



PRAY FOR JAPAN



Wiring Strategy in CTO-PCI

Pre-procedural Examination of Angiogram w/wo MSCT

Antegrade approach

1. Single wire manipulation
2. Parallel wiring
3. IVUS guided wiring

Failure

Retrograde approach

1. Wiring through collateral
2. Retrograde wiring
 - Retrograde wire crossing
 - Kissing wire technique
 - Knuckle wire technique
 - CART
 - Reverse CART

Complex CTO



Current choice of 1st Wire in Antegrade Approach



Previous: Spring coil wires (Floppy wire or Miracle 3g) with micro-catheter as a first choice.

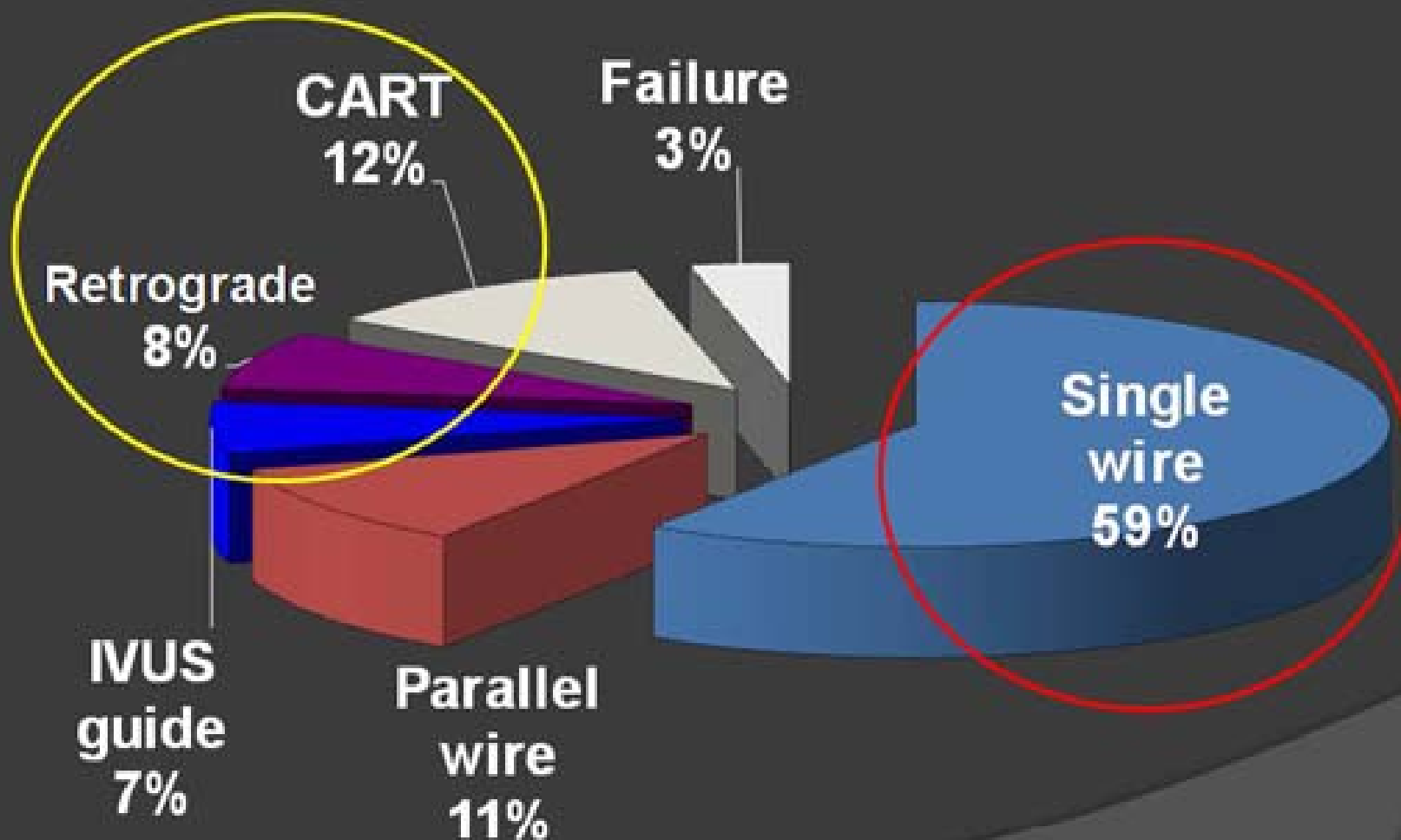
Now: Hydrophilic coated wire (Fielder FC or Fielder XT) as a first choice in Toyohashi Heart Center.

If failed, exchange to a stiffer wire (Miracle 12g or Conquest).



Crossed Wiring Technique in THO

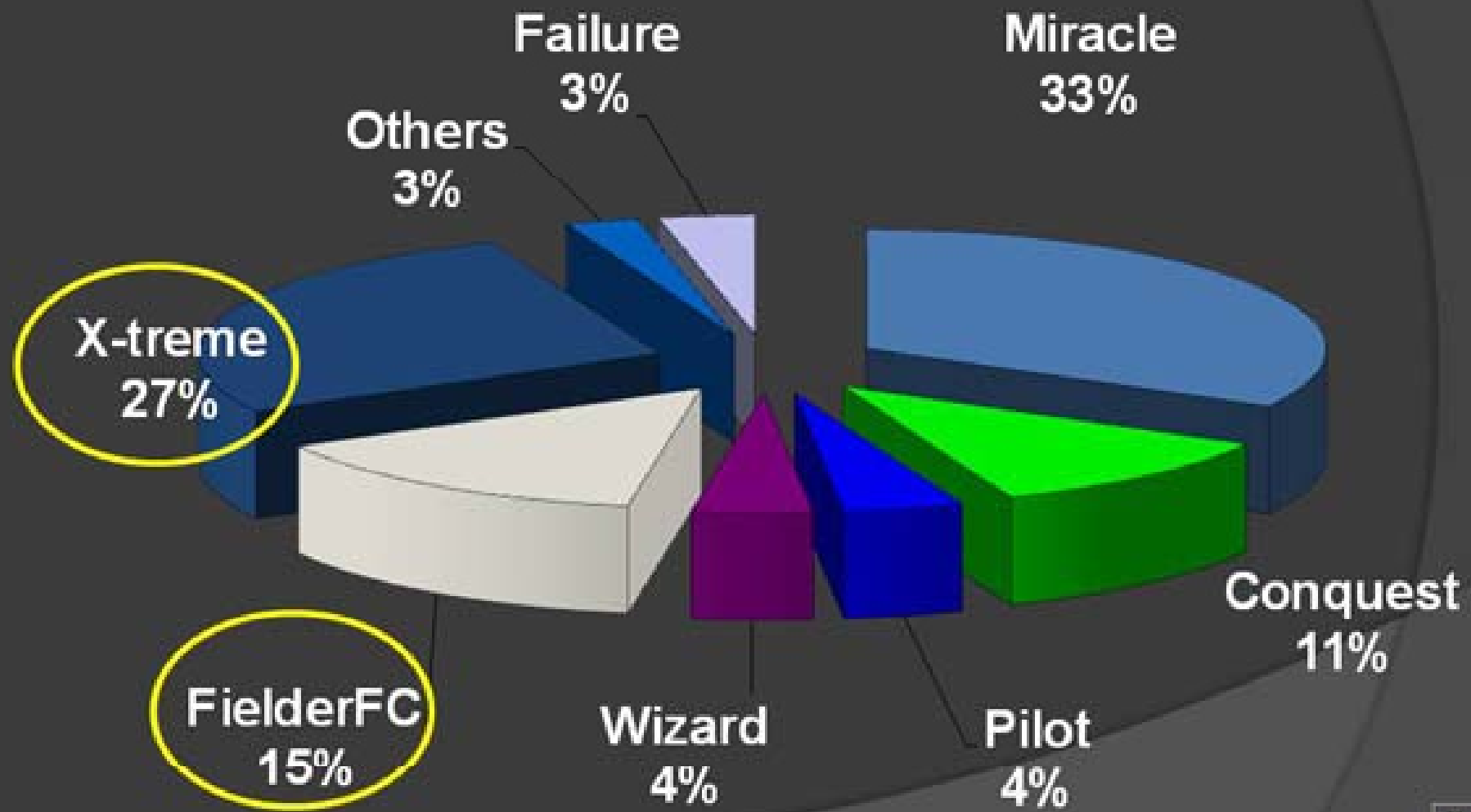
(2009, n=118)





Crossing Guide Wire in THC

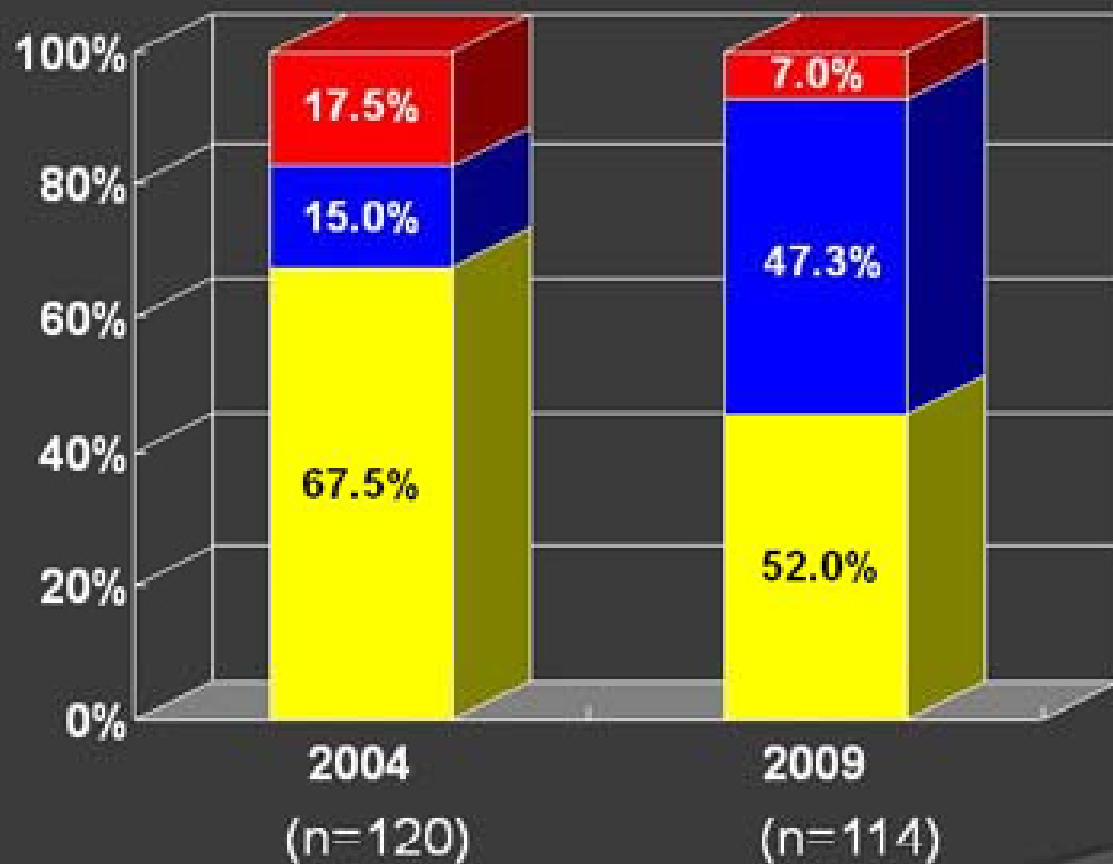
(2009, n=118)





Crossing Guide Wire in THC

(2009, n=118)



- Spring coil floppy wire
- Plastic jacket wire
- Spring coil CTO wire



Wiring Strategy in CTO-PCI

Pre-procedural Examination of Angiogram w/wo MSCT

Antegrade approach

1. Single wire manipulation
2. Parallel wiring
3. IVUS guided wiring

Retrograde approach

1. Wiring through collateral
2. Retrograde wiring
 - Retrograde wire crossing
 - Kissing wire technique
 - Knuckle wire technique
 - CART
 - Reverse CART



Current CTO Wiring Strategy

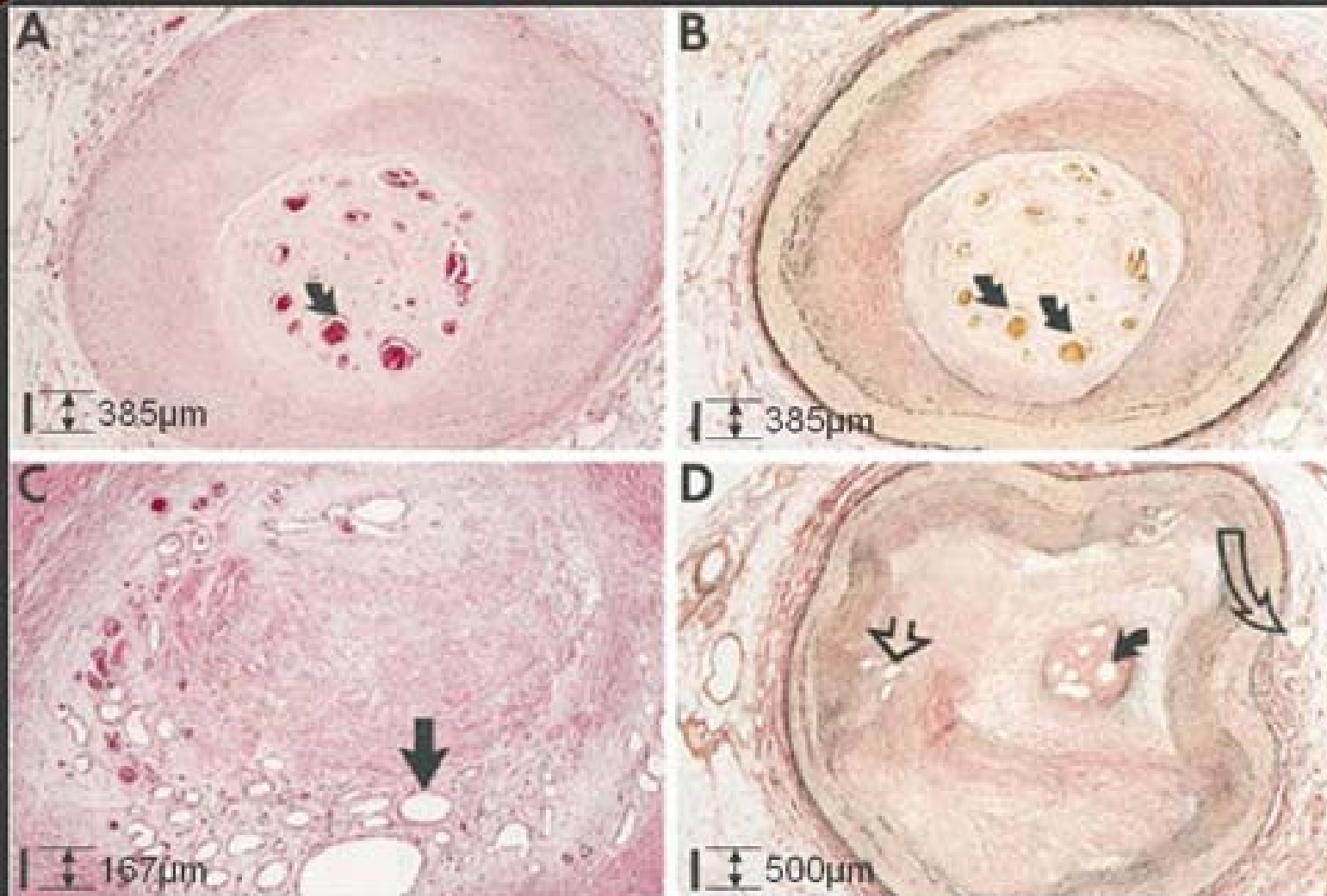
Fielder **XT**

a small tip slippery wire

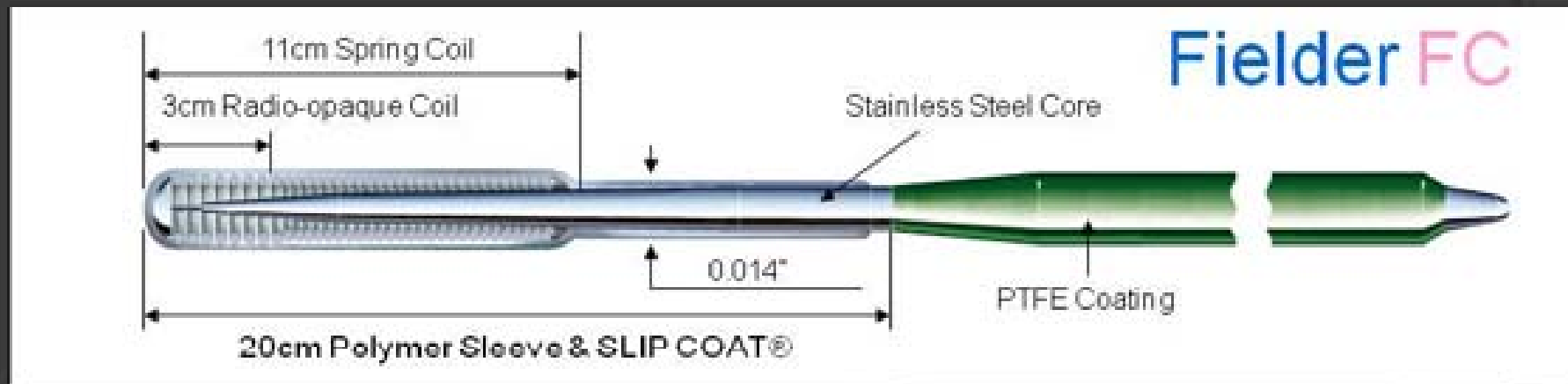
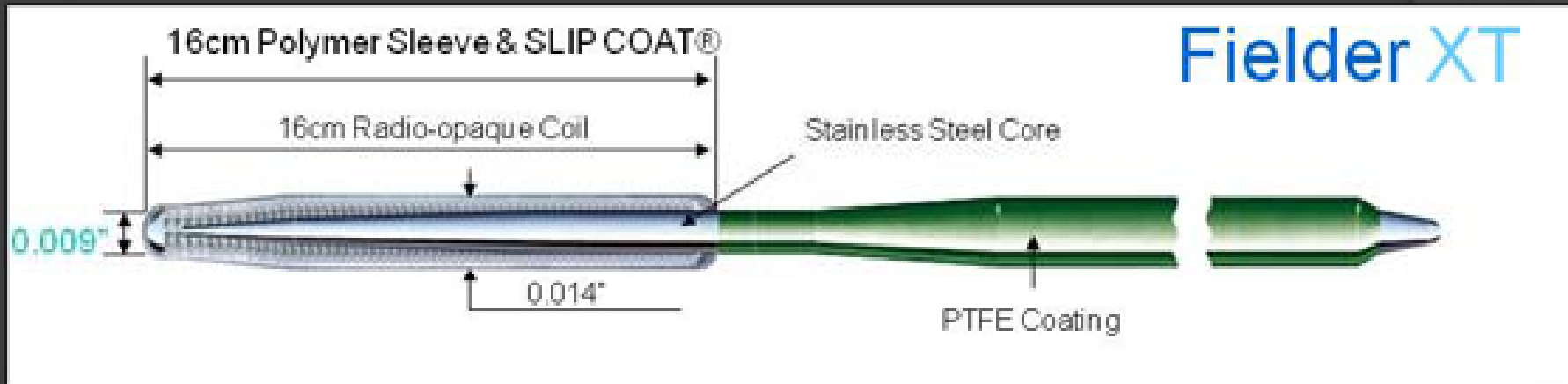




Micro Channels in CTOs

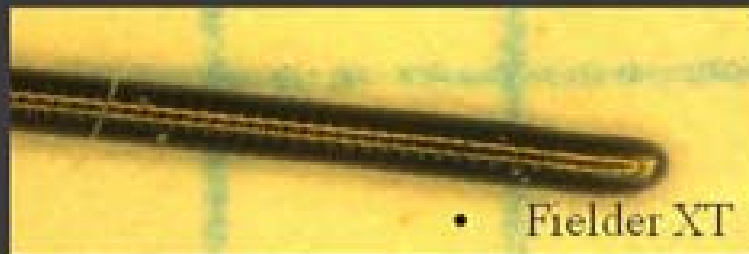
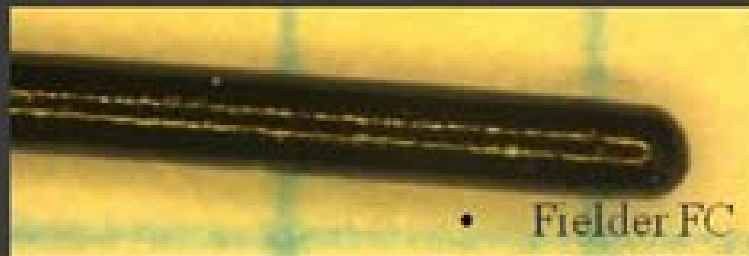



- Histological average size is 200µm (0.008 inch)


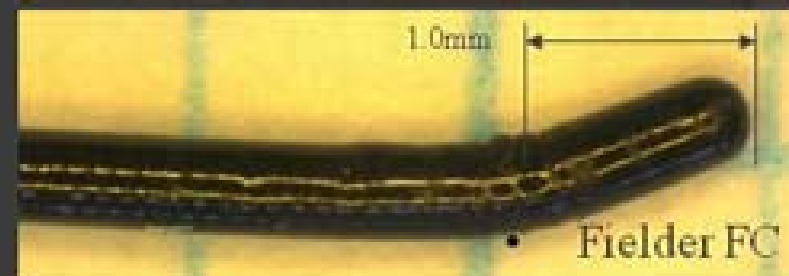
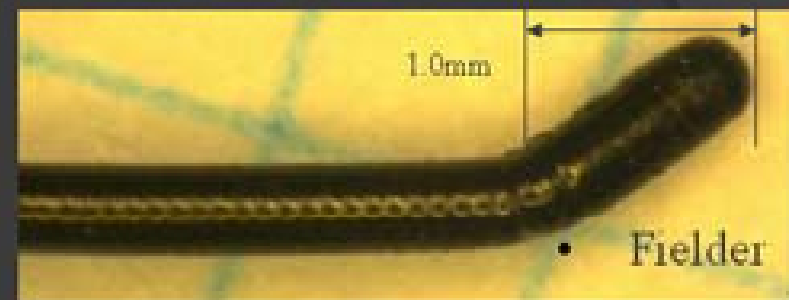




Before Shaping



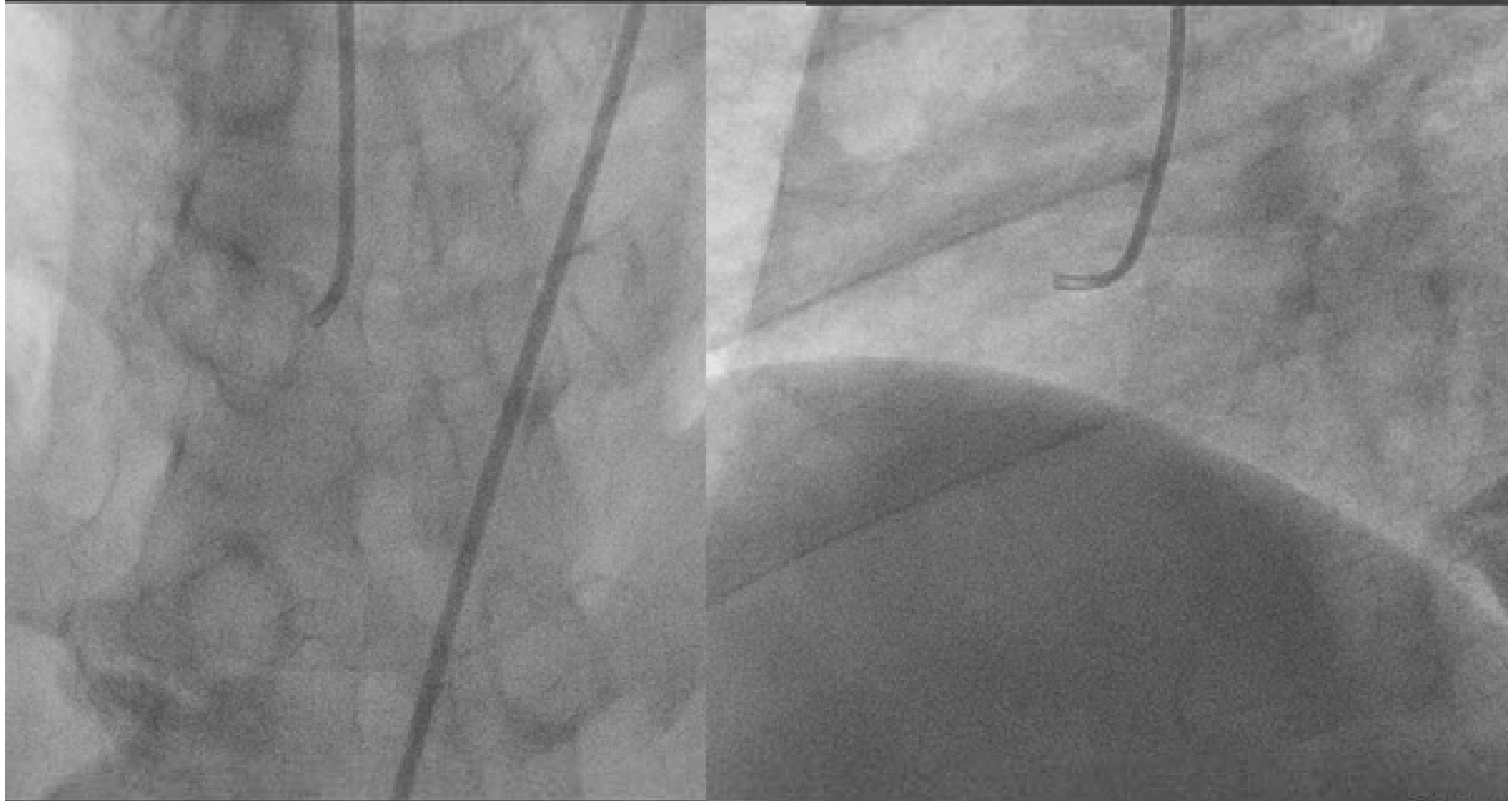
After Shaping



Fielder XT enables precise tip shaping due to its short soldering tip

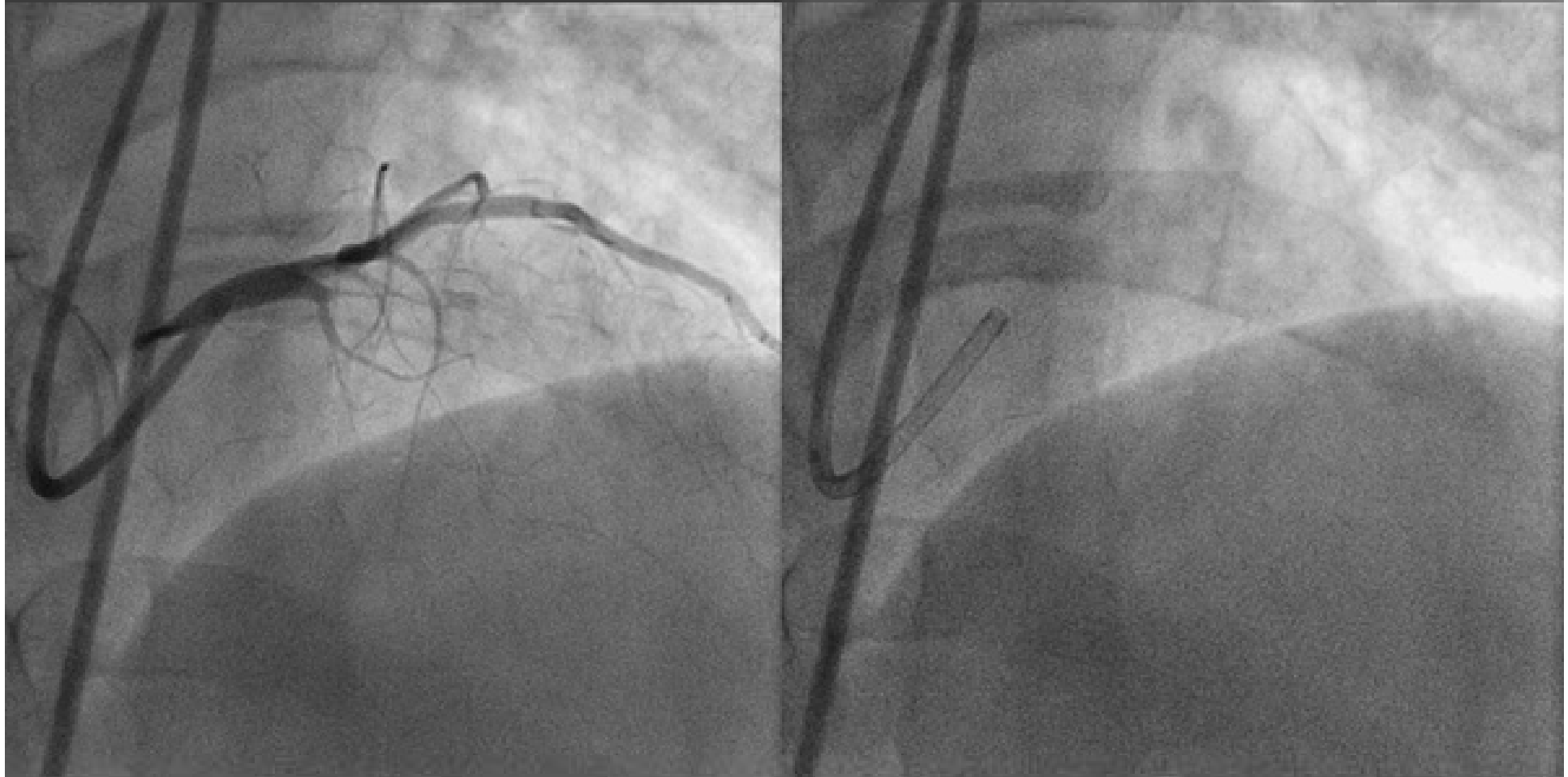


CONTRA-LATERAL INJECTION



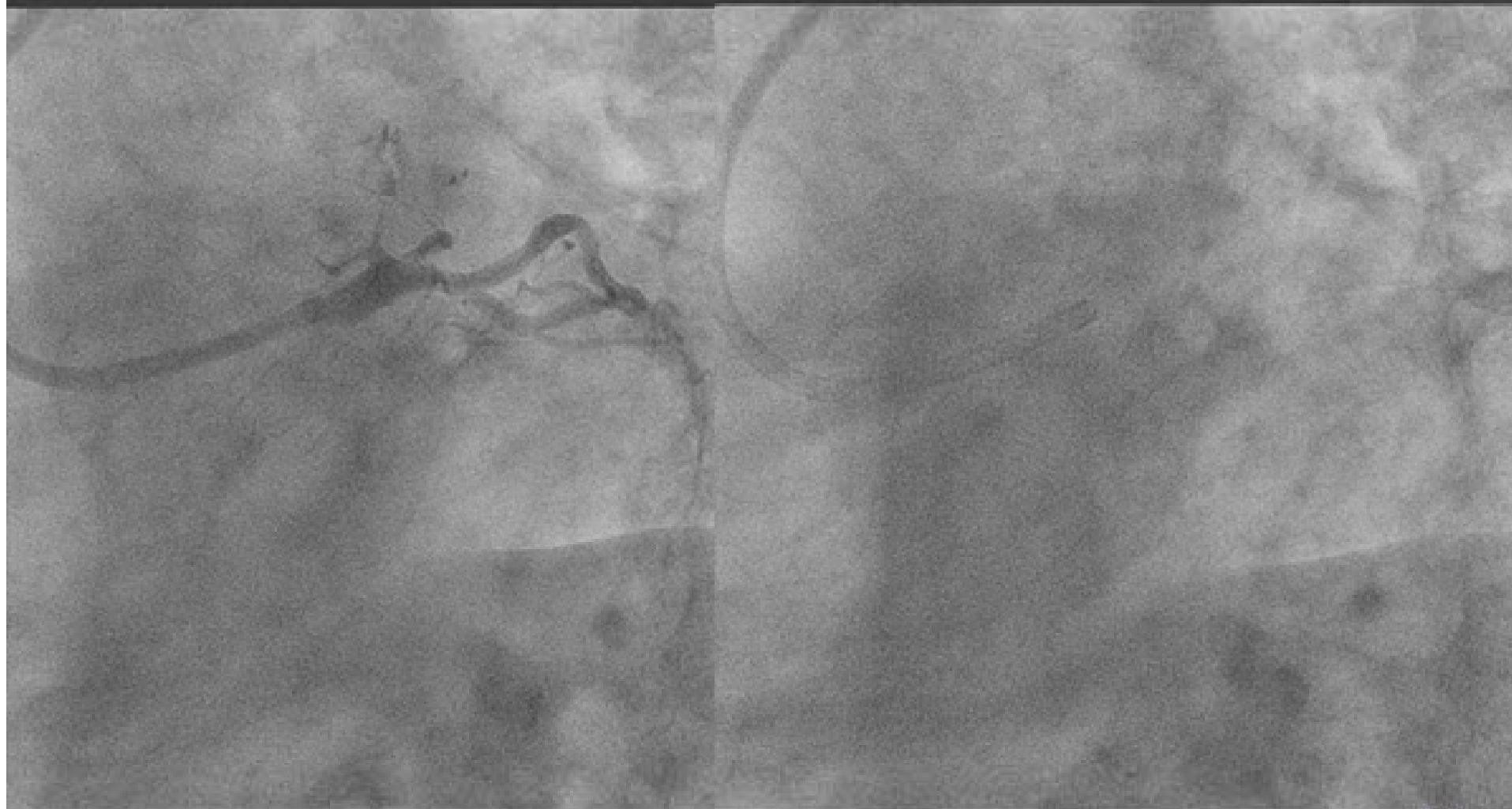


LAD SUB TOTAL?



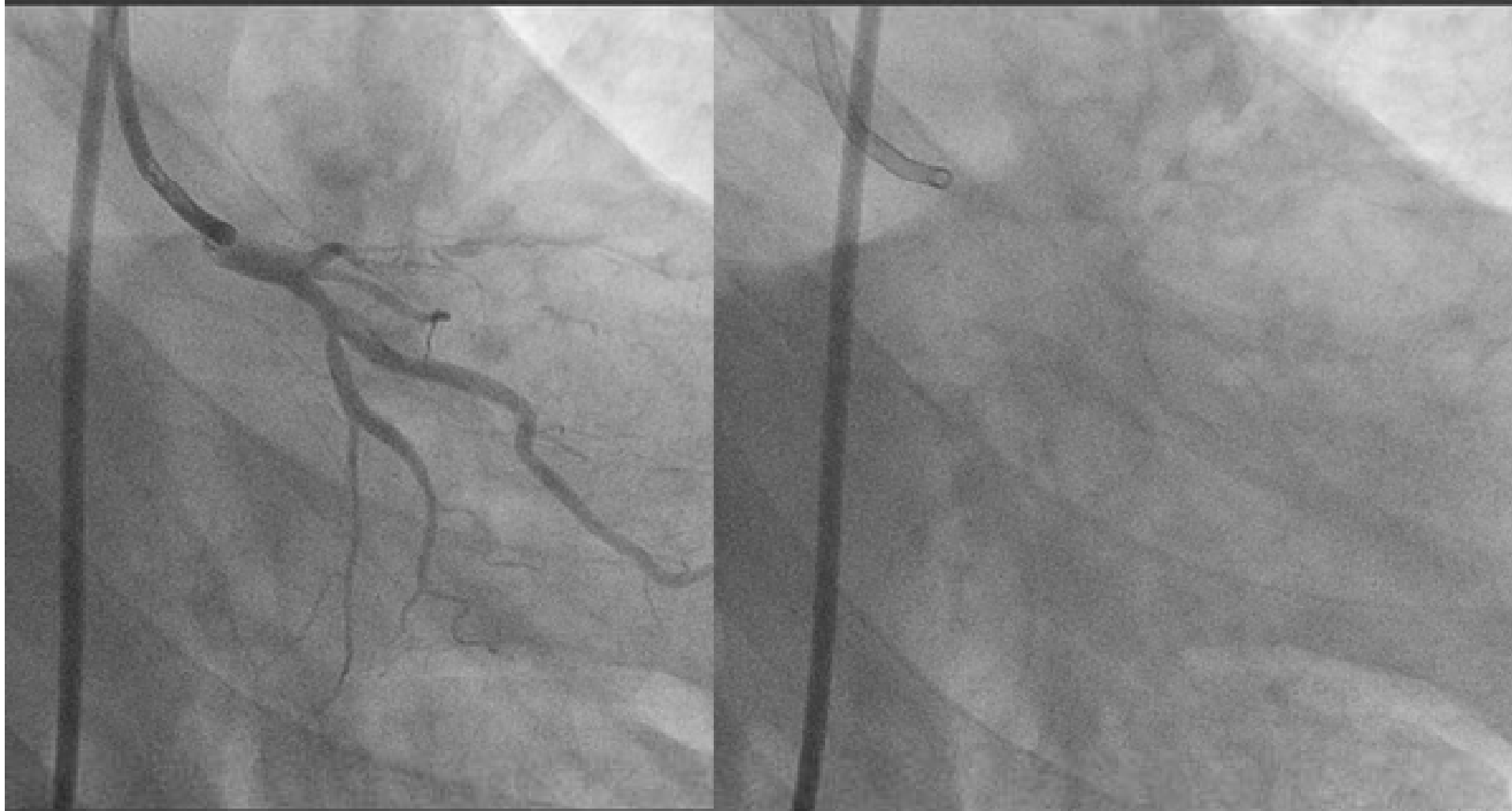

LAD SUB TOTAL?



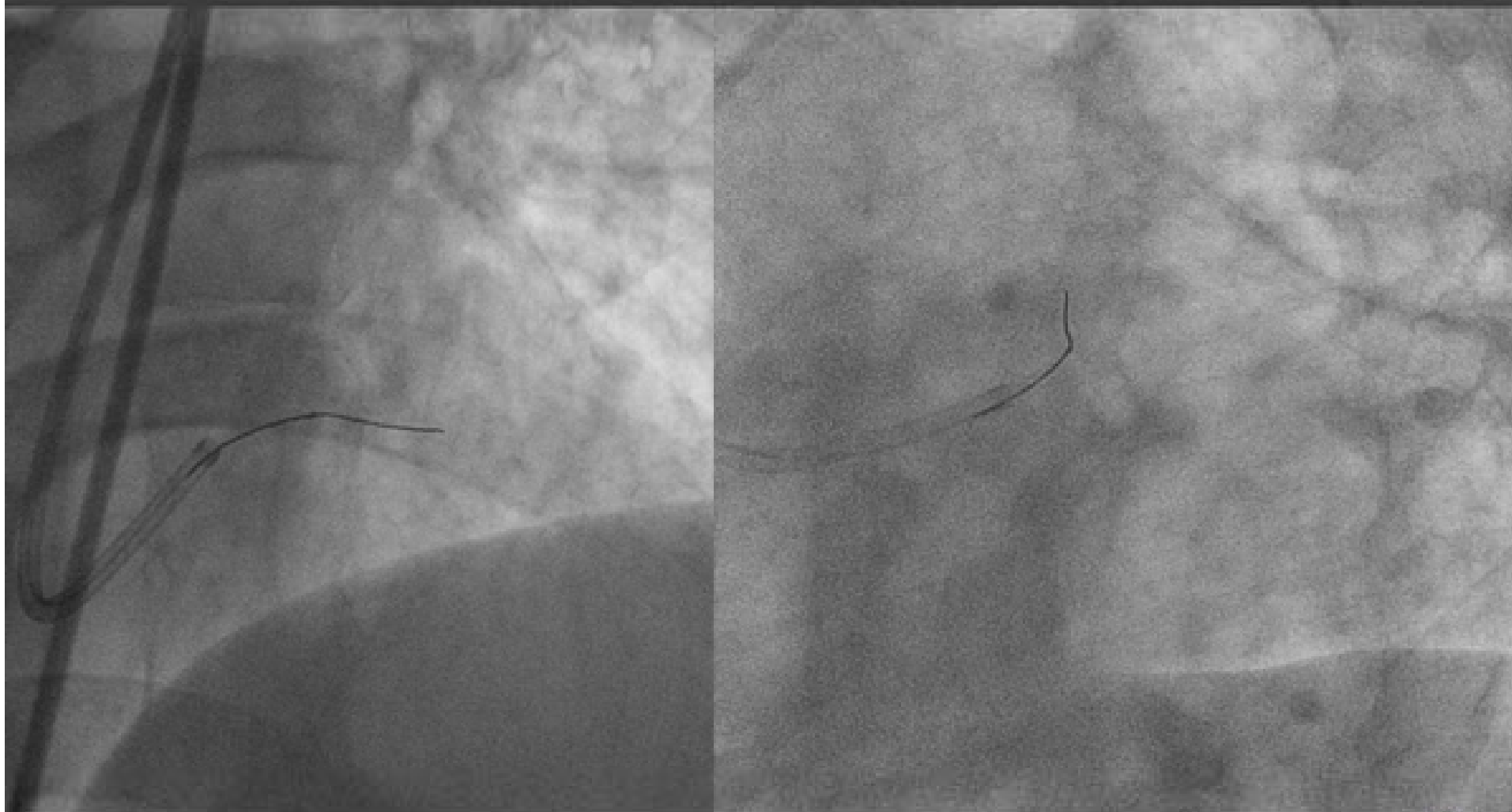


LAD SUB TOTAL?



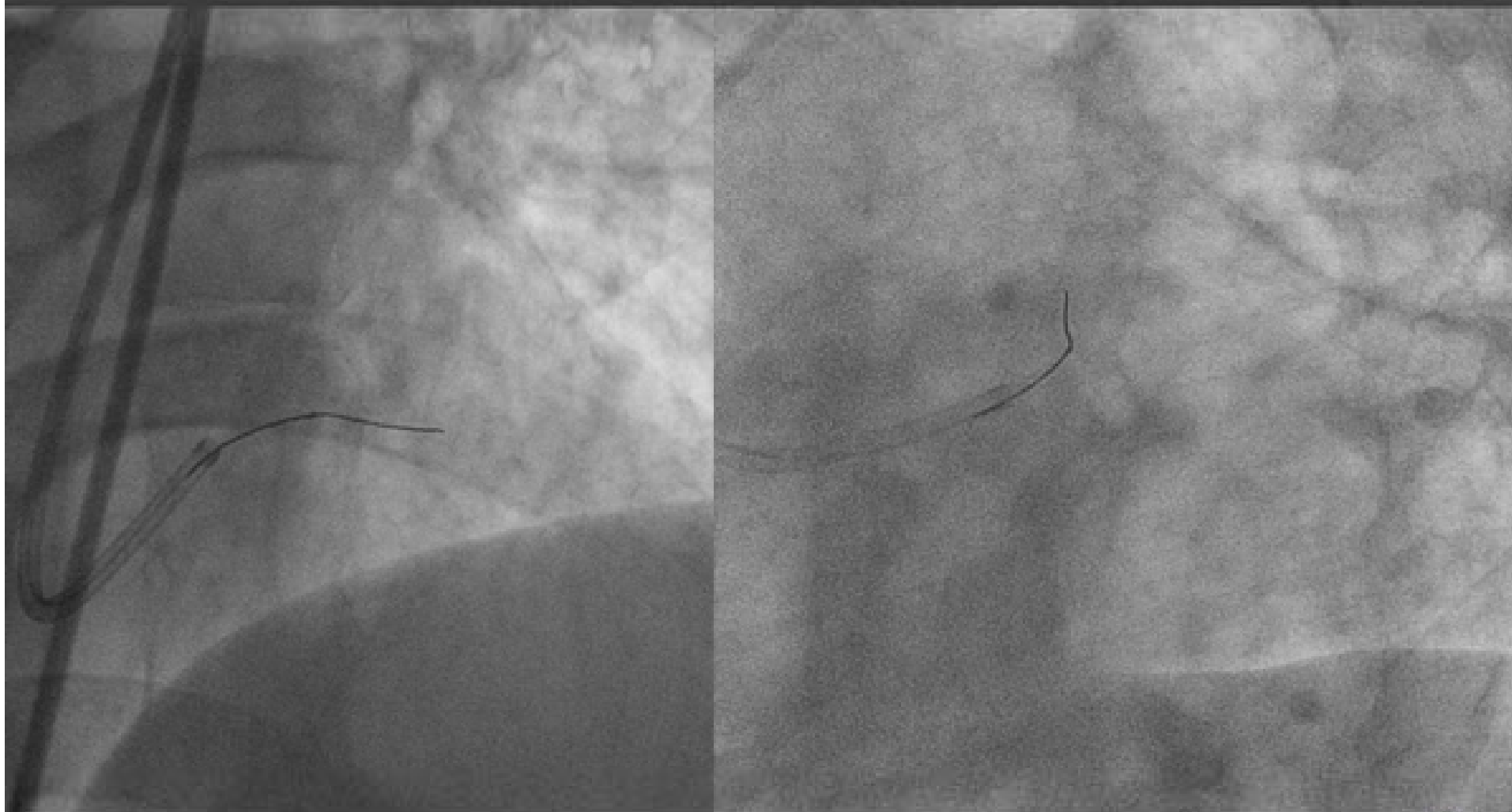


FIELDER FC+FINECROSS



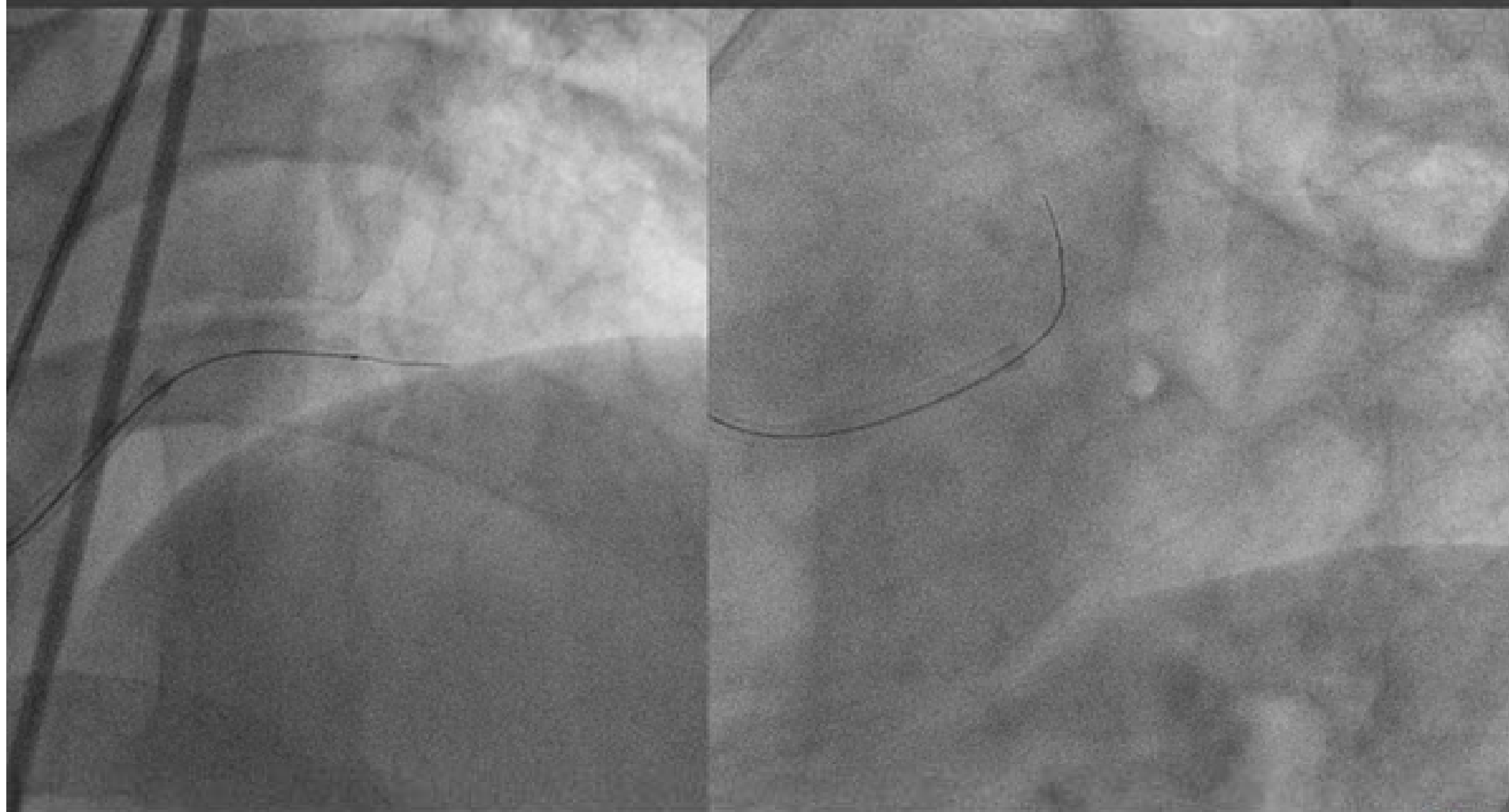


FIELDER FC+FINECROSS



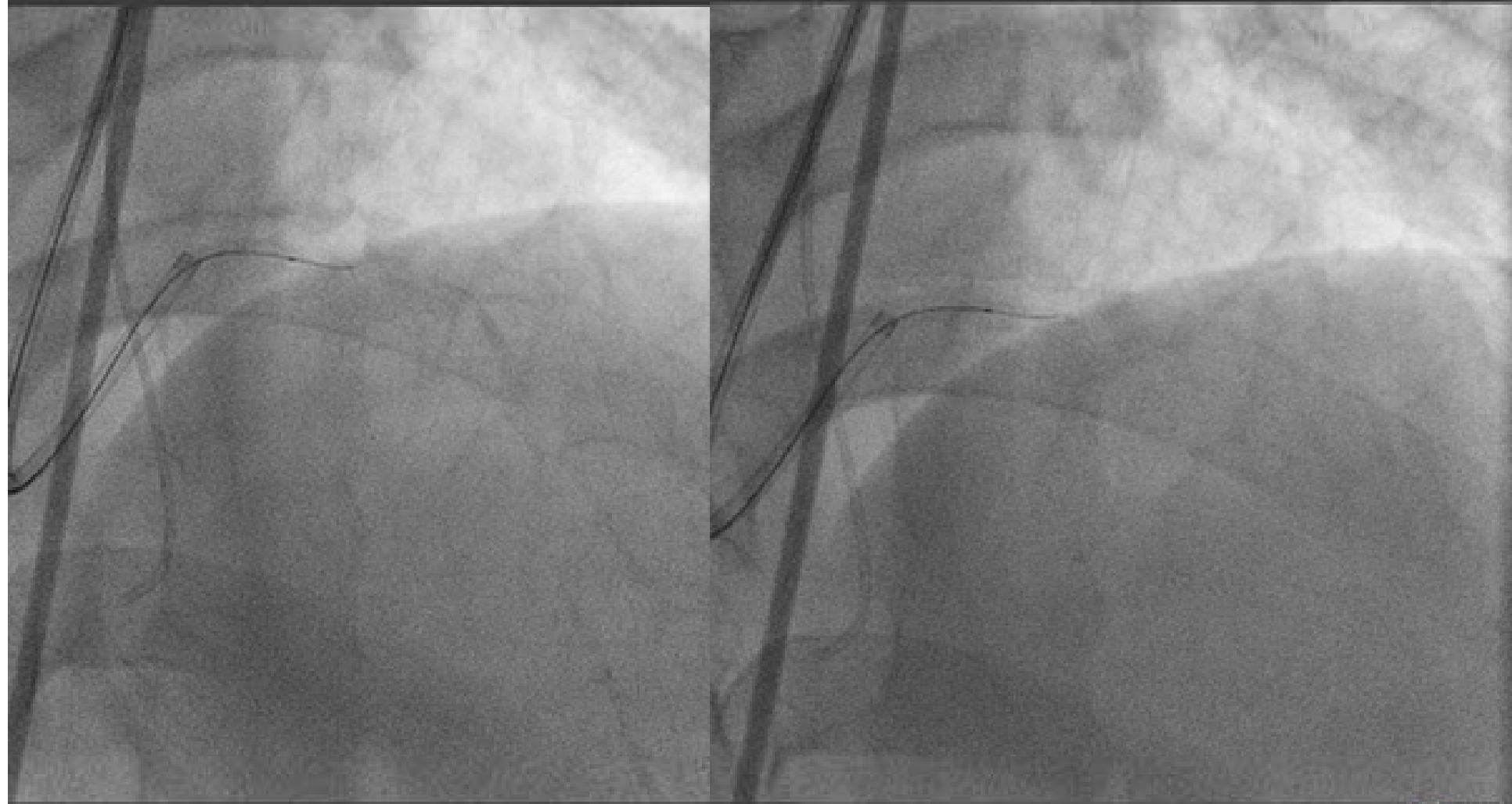


FIELDER XT+FINECROSS



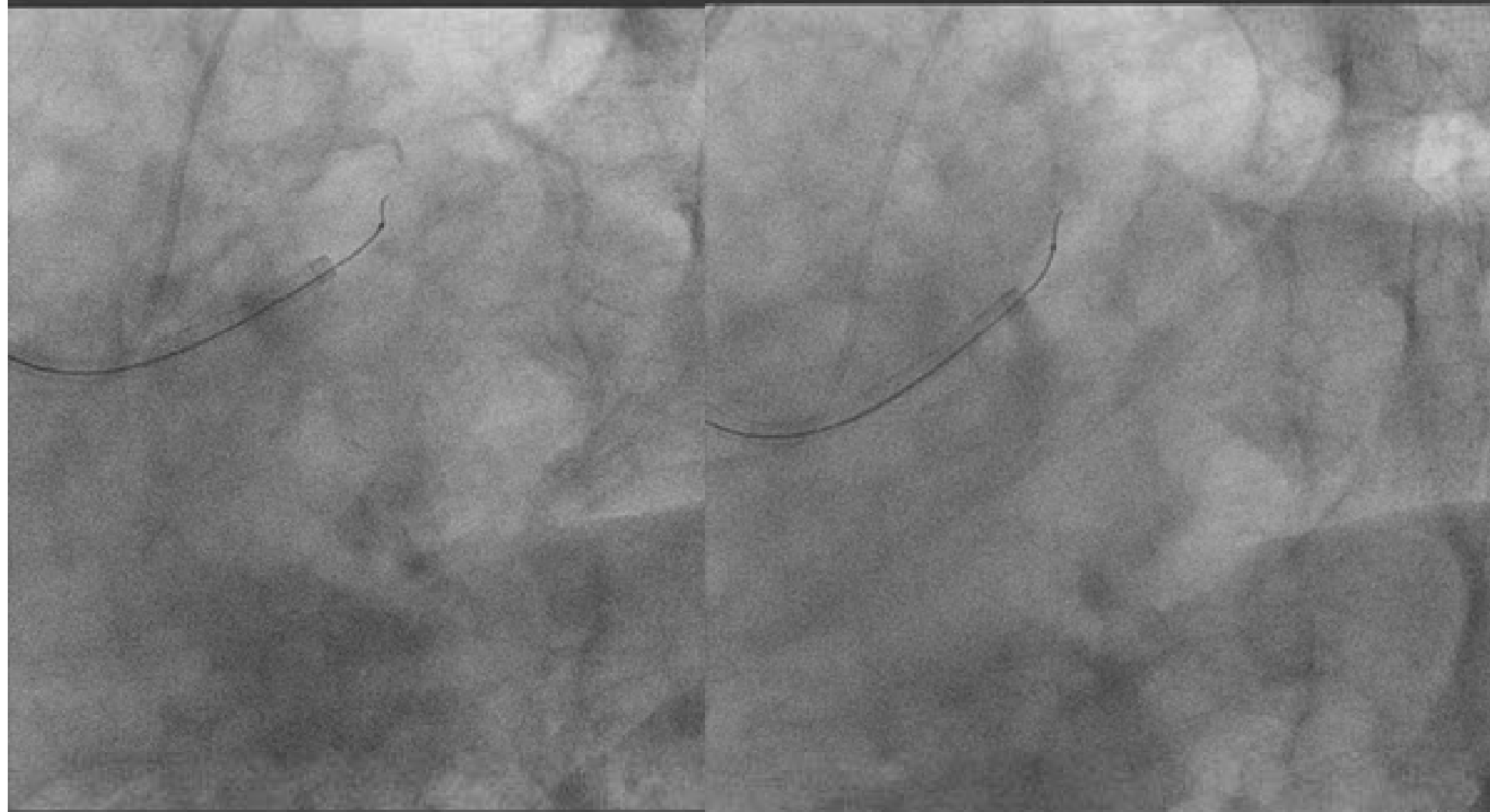


MORE UPPER



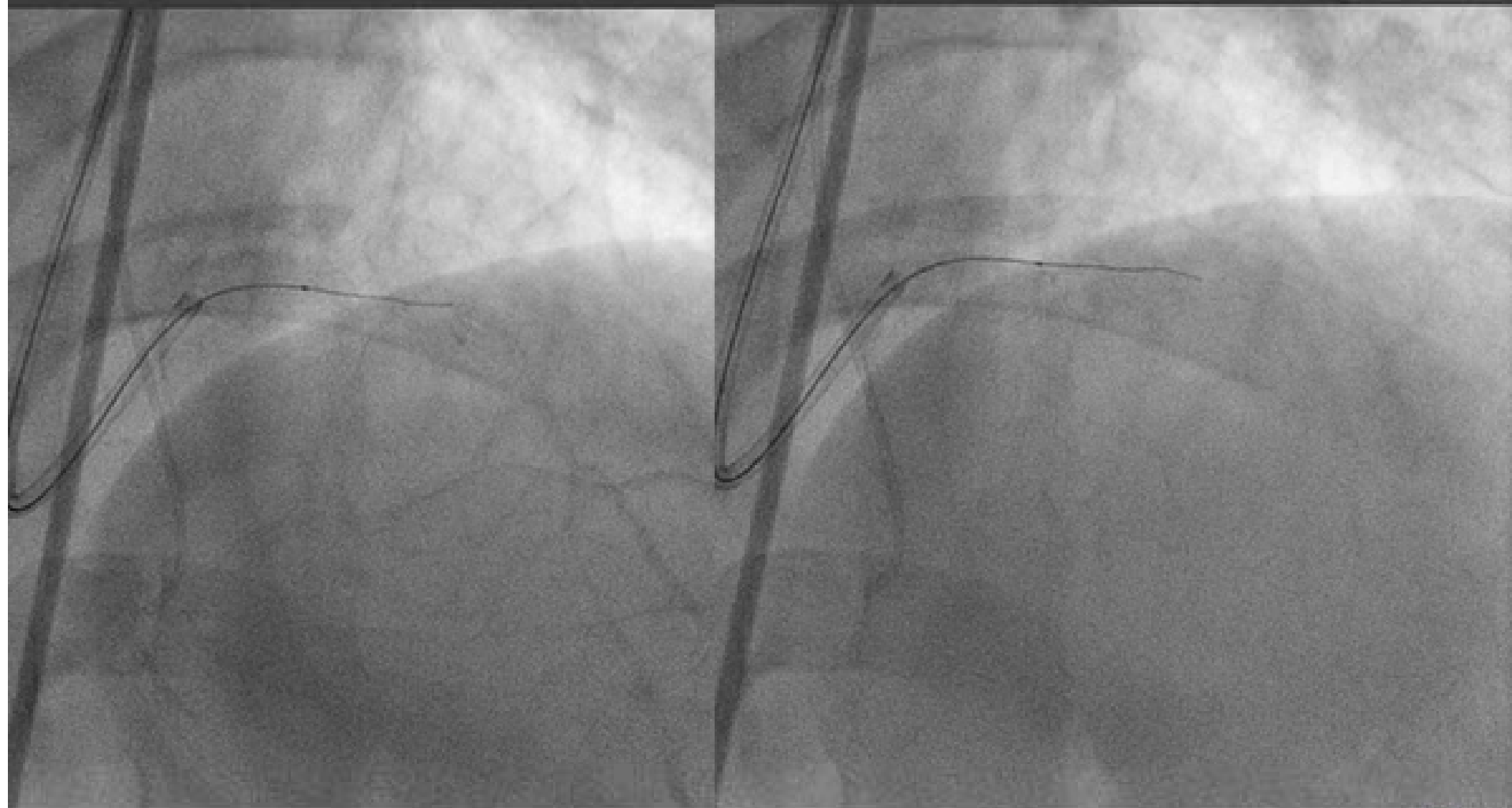


MORE RIGHT!



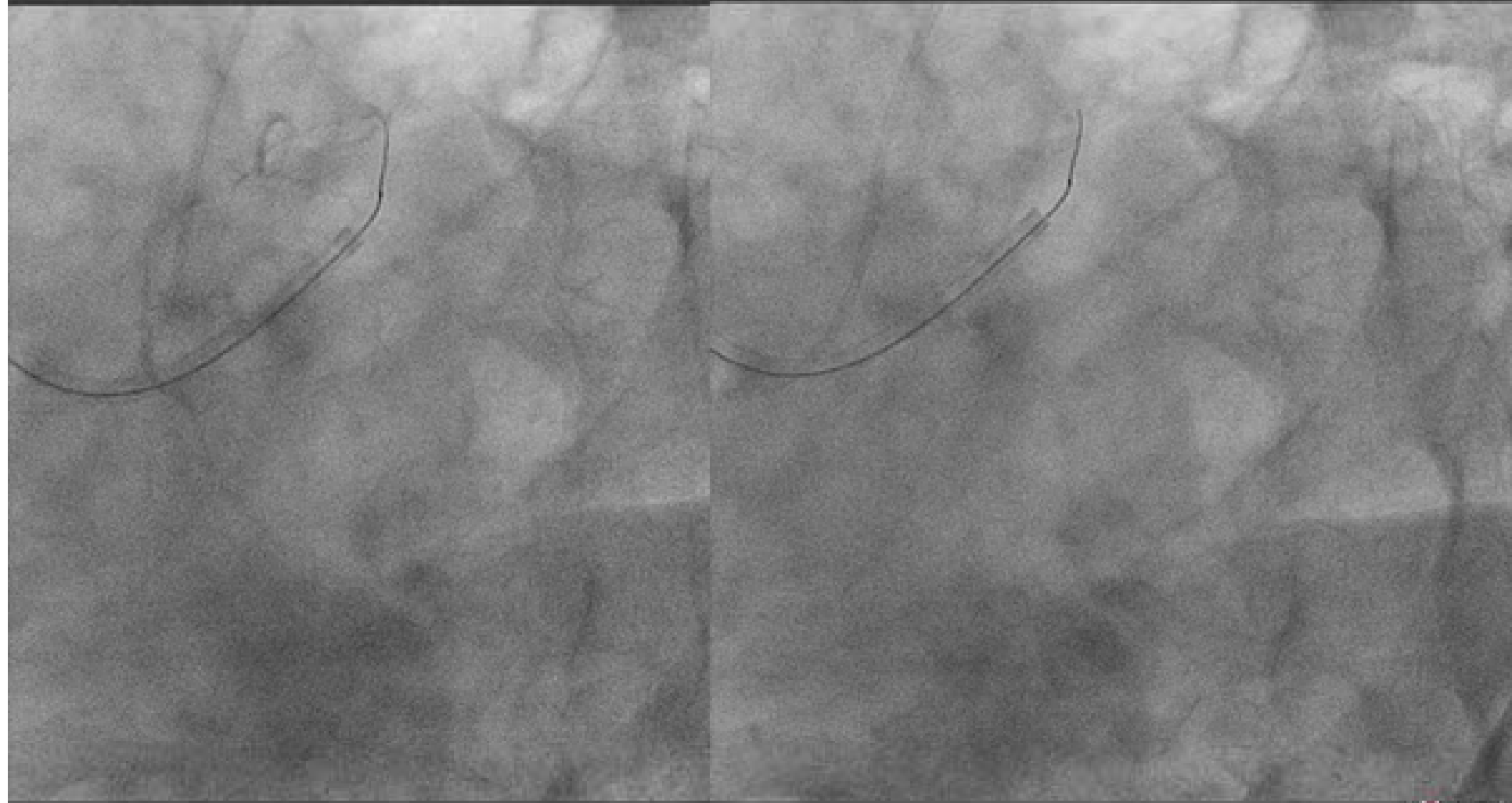


STILL IN SUB....





STILL IN SUB....





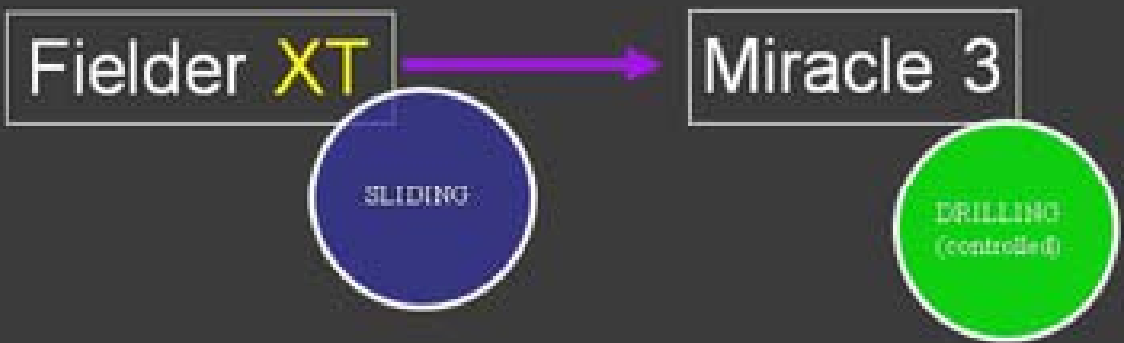
Micro Channel Tracking as 1st Attempt



- First, you should advance a support catheter proximal to CTO.
- Even when any visible channel can not be seen, you may attack the occlusion by a small tip slippery wire (Fielder **XT**).
- If it can **not** be advanced into the CTO, please change to a CTO wire (Miracle 3).
- If it can be advanced, you may continue the wiring supported by catheter because it's **less traumatic**.



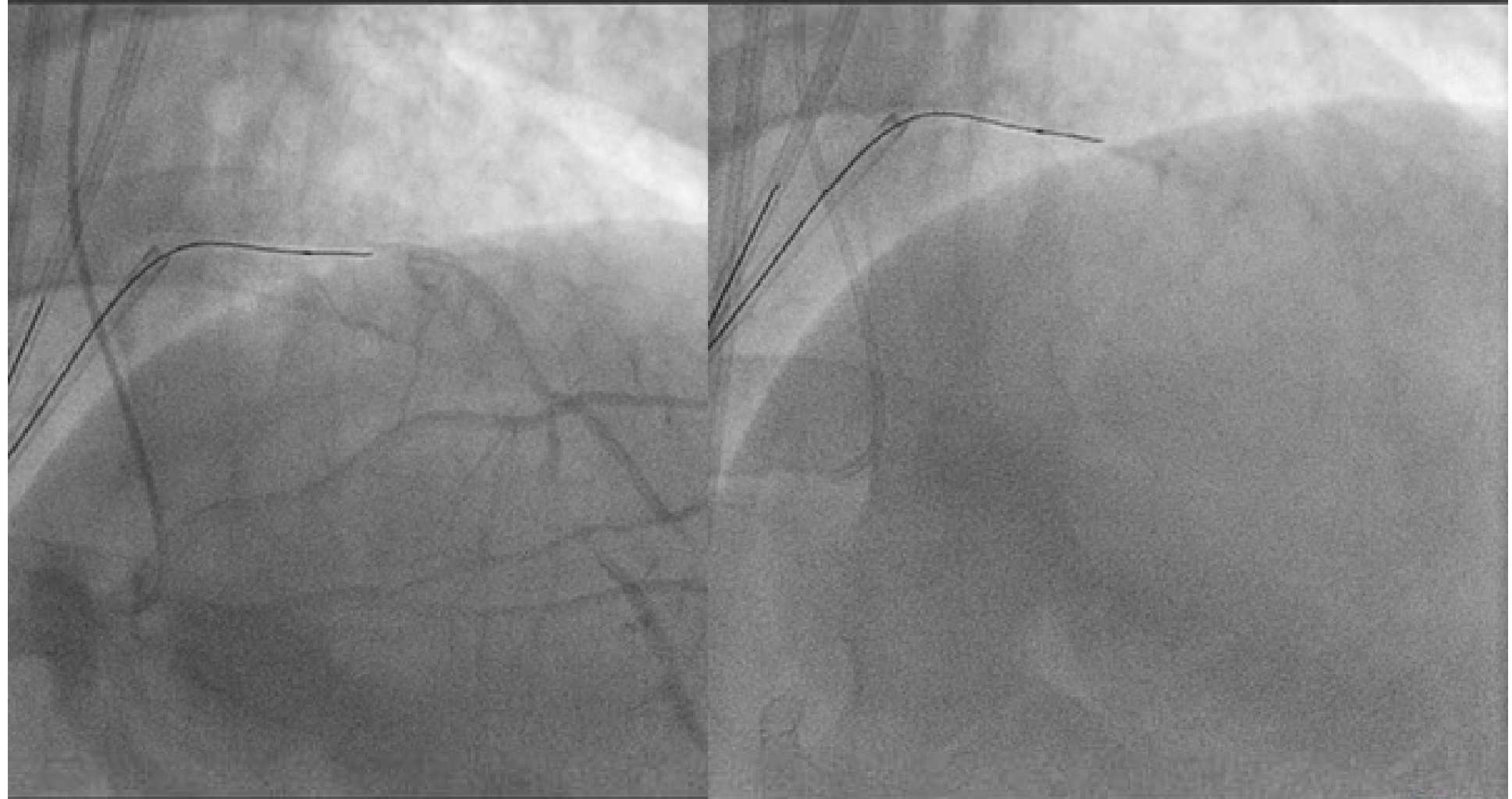
Current CTO Wiring Strategy



 *Unsuccess
(Not advanced)*

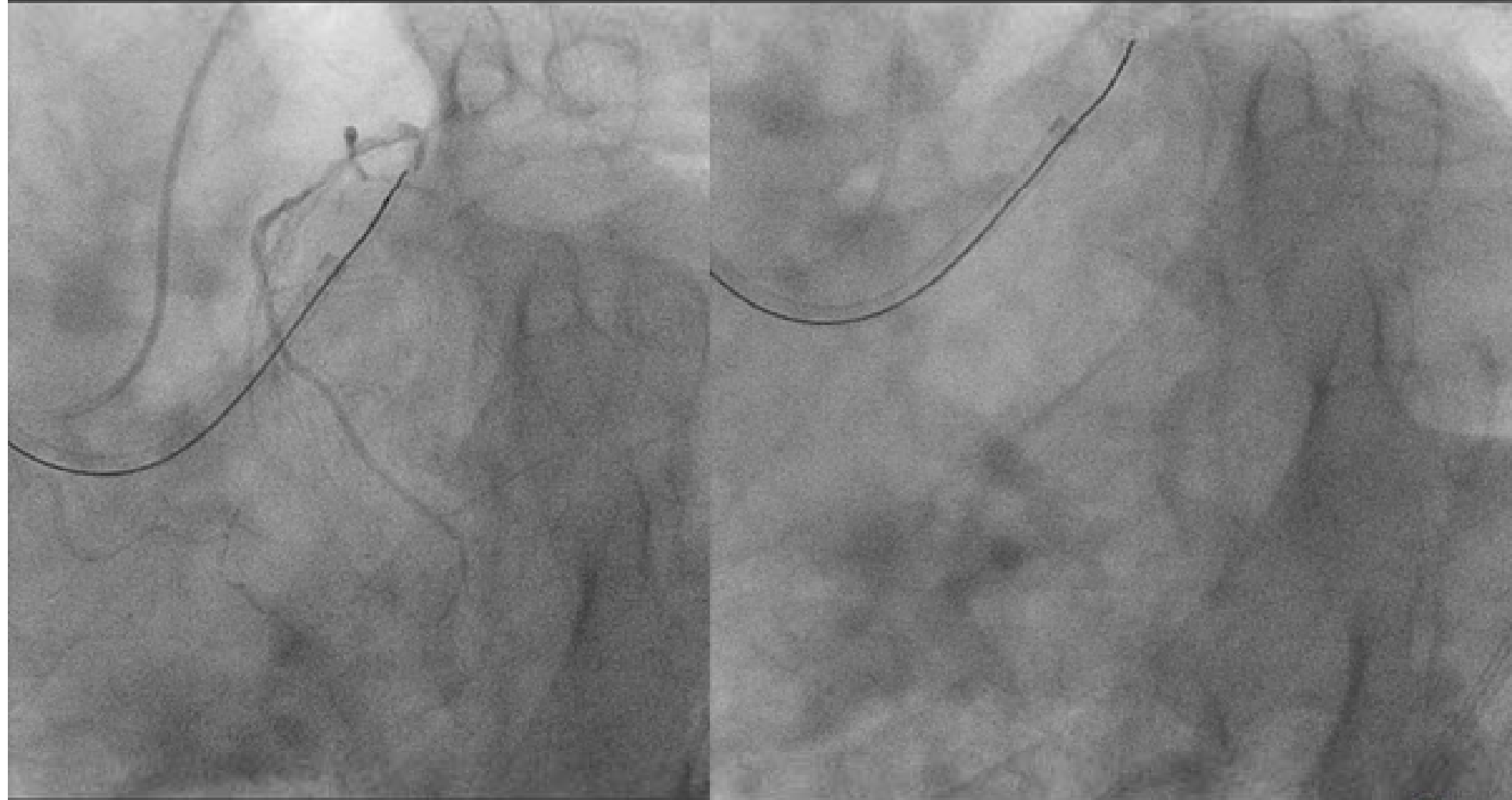


MIRACLE 3G





MIRACLE 3G





Wiring Strategy in Retrograde Approach Era



Pre-procedural Examination of Angiogram w/wo MSCT

Antegrade approach

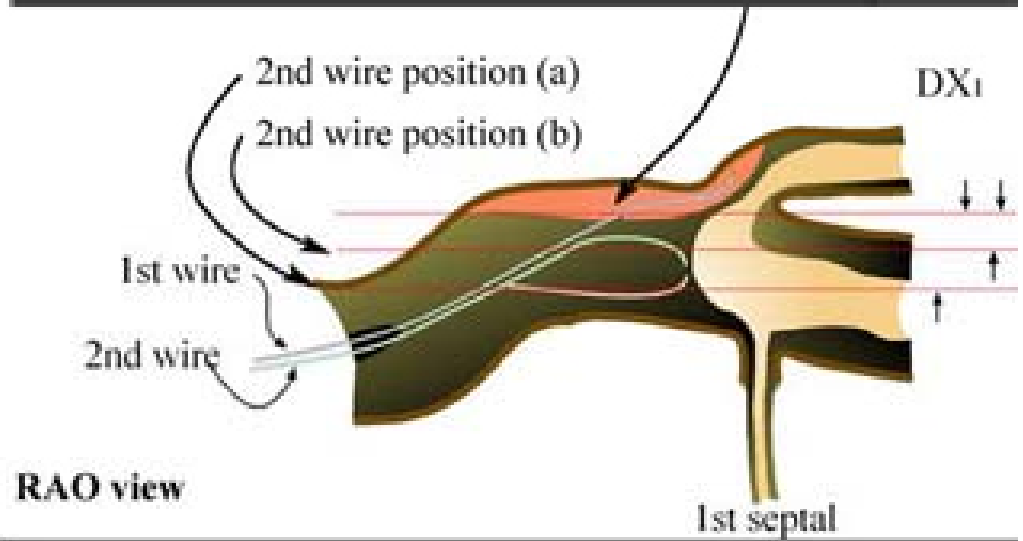
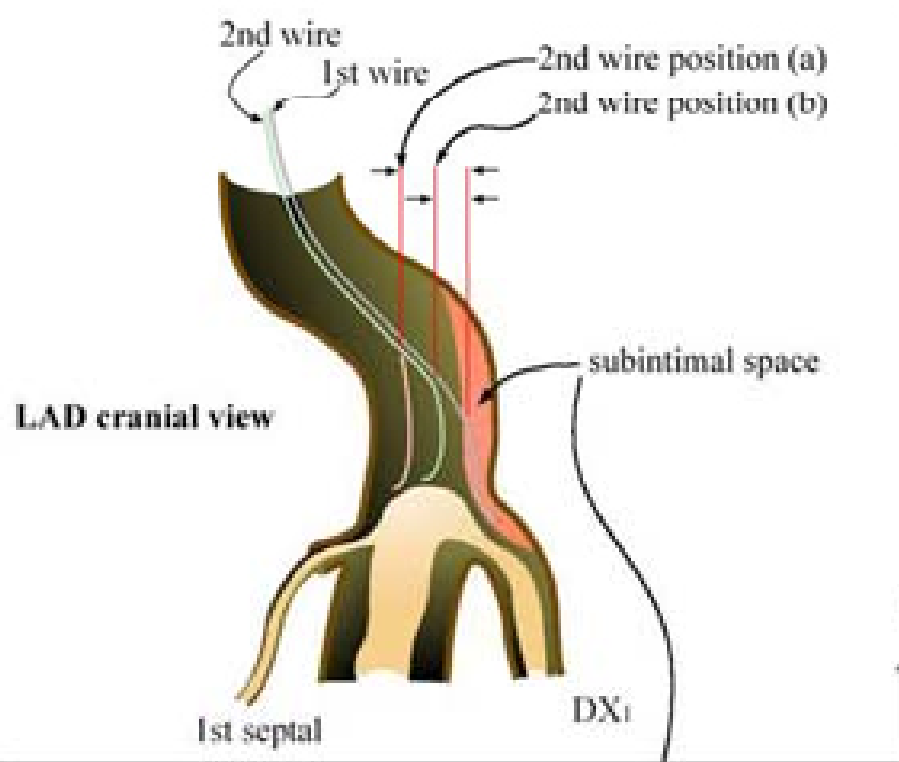
1. Single wire manipulation
2. Parallel wiring
3. IVUS guided wiring

Retrograde approach

1. Wiring through collateral
2. Retrograde wiring
 - Retrograde wire crossing
 - Kissing wire technique
 - Knuckle wire technique
 - CART
 - Reverse CART

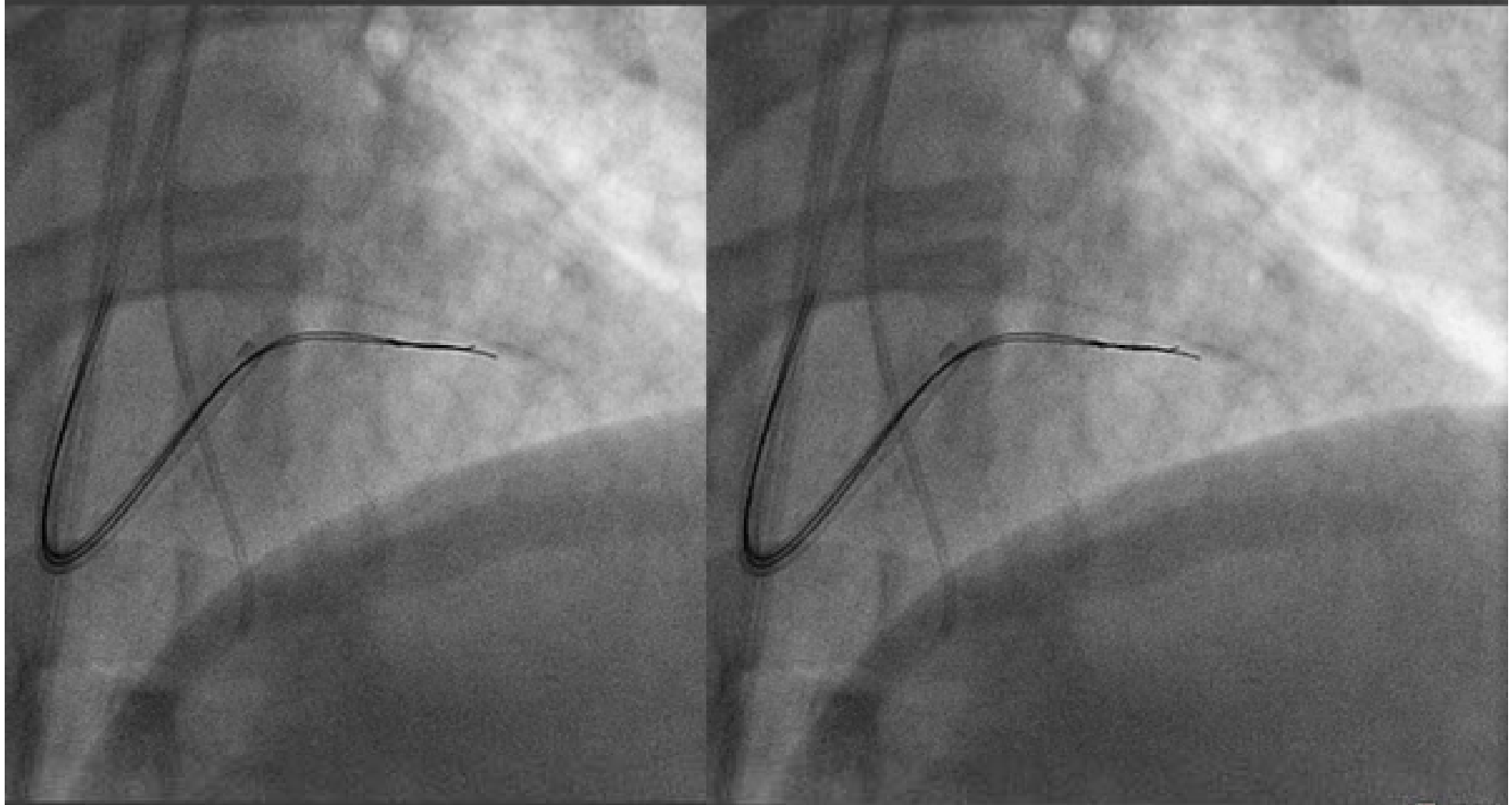


Concept of Parallel Wire Technique



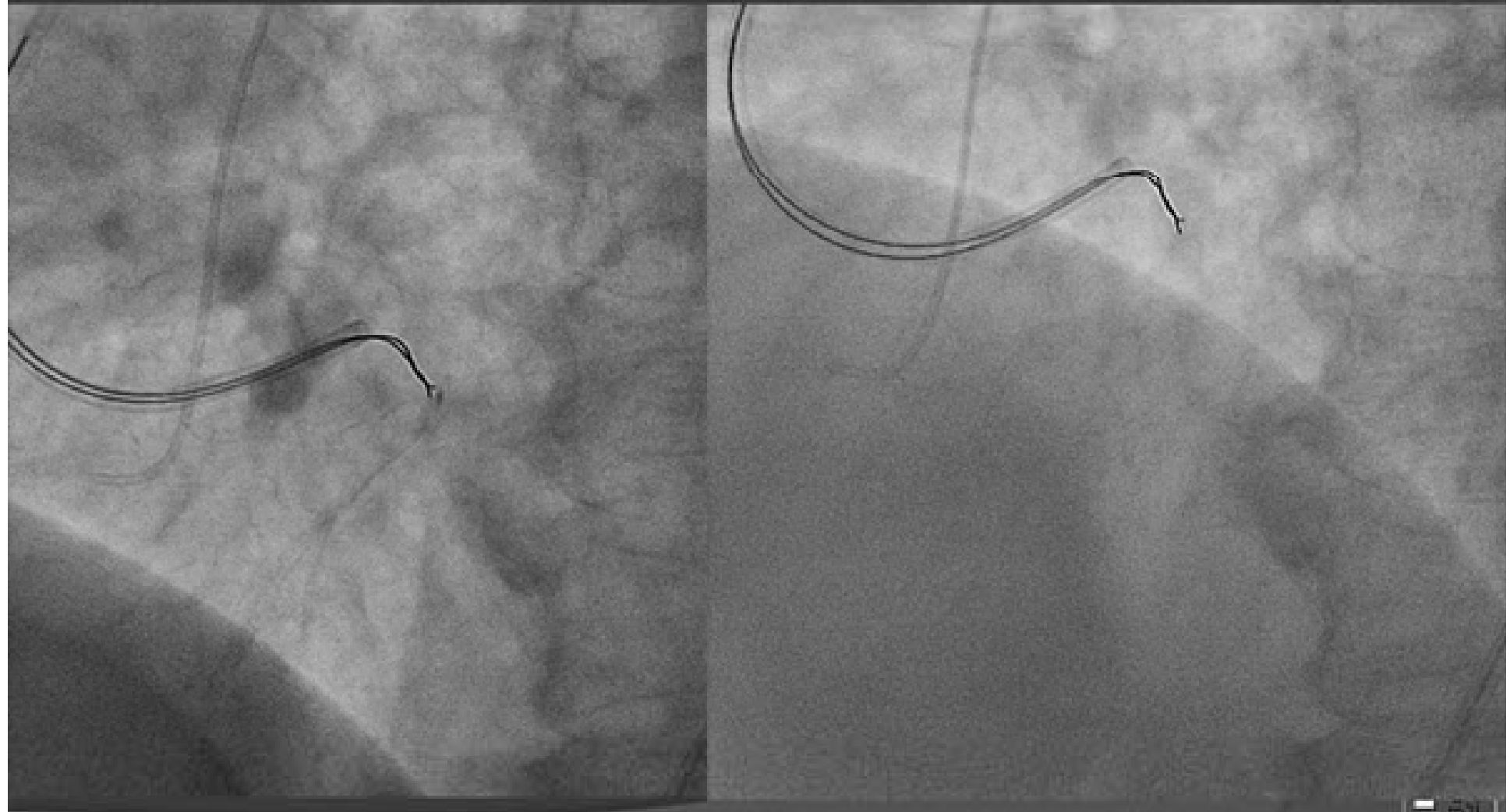


MIRACLE 3G PARALLEL



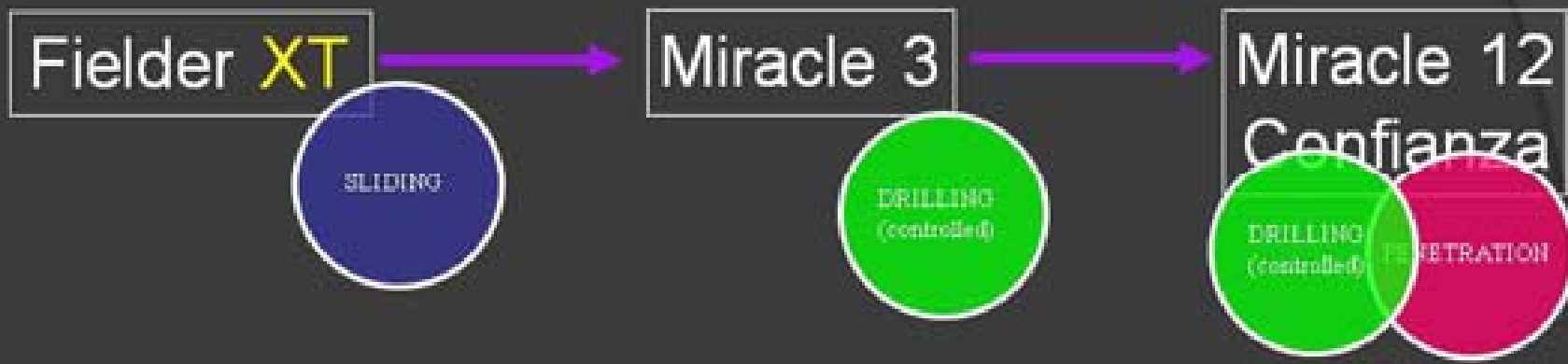

MIRACLE 3G PARALLEL





Current CTO Wiring Strategy

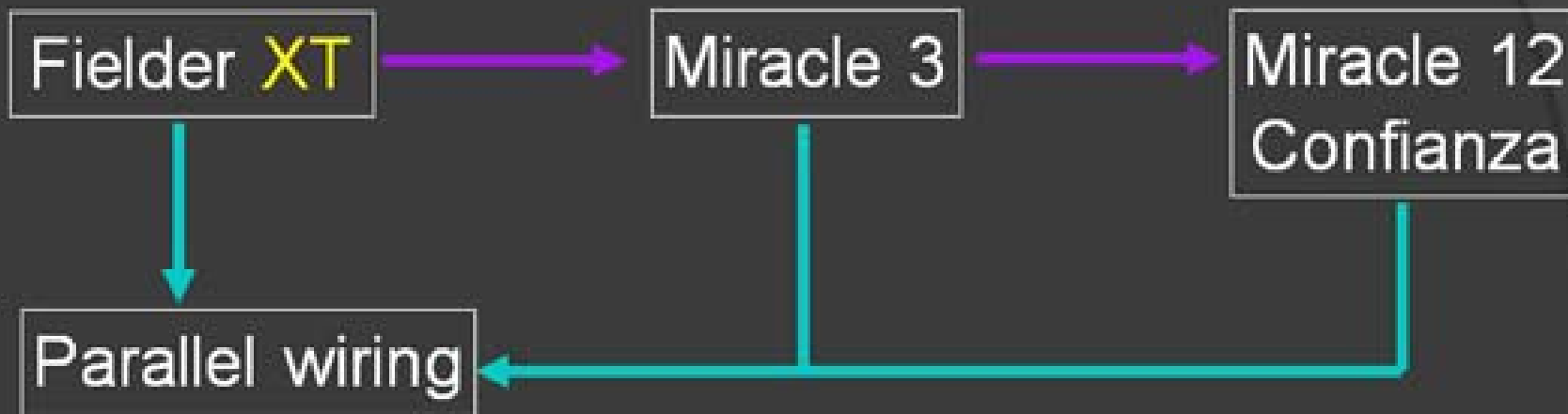


→ *Unsuccess
(Not advanced)*

→ *Failure
(Subintimal tracking)*



Current CTO Wiring Strategy



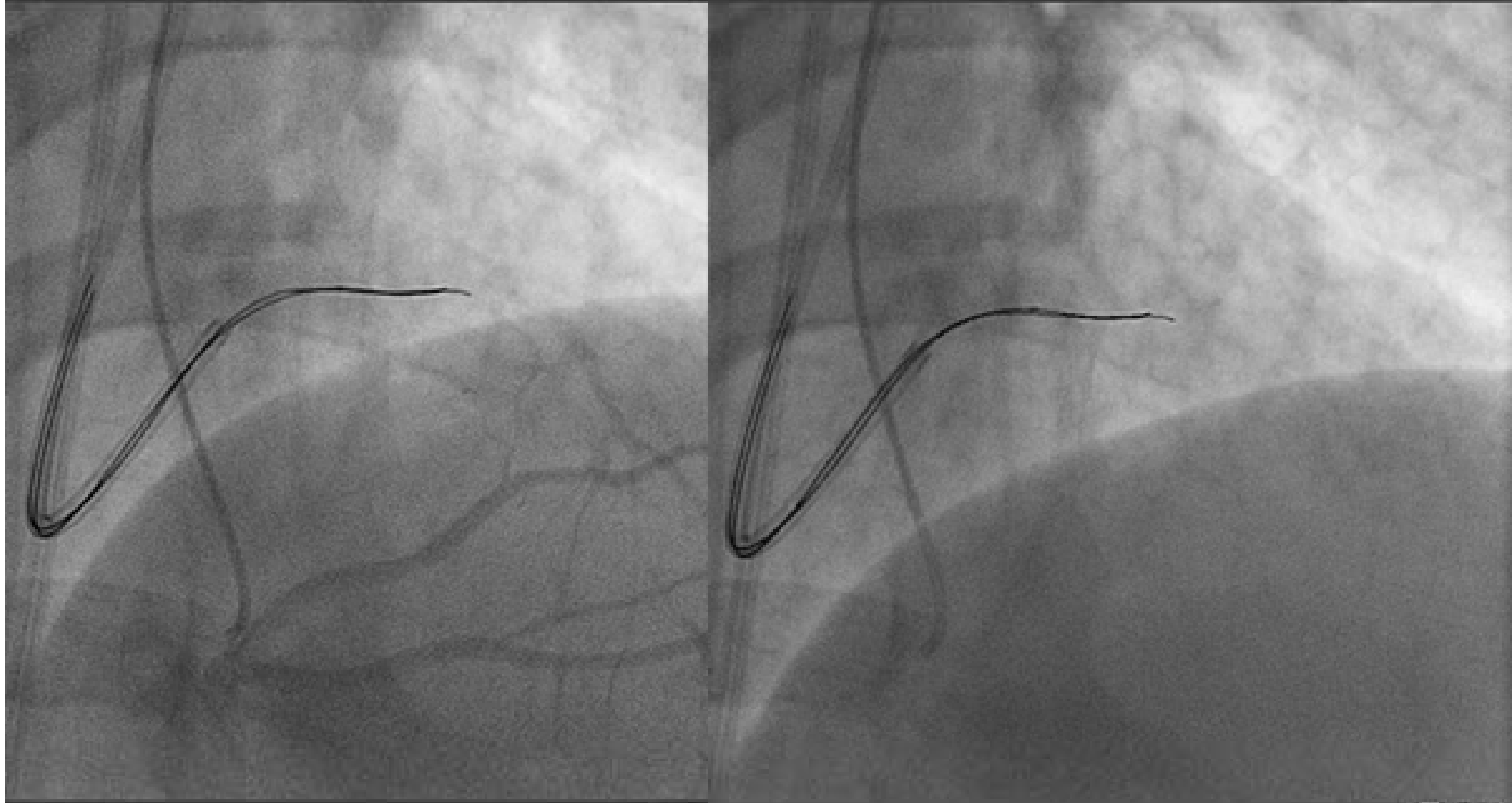
→ *Unsuccess
(Not advanced)*

→ *Failure
(Subintimal tracking)*



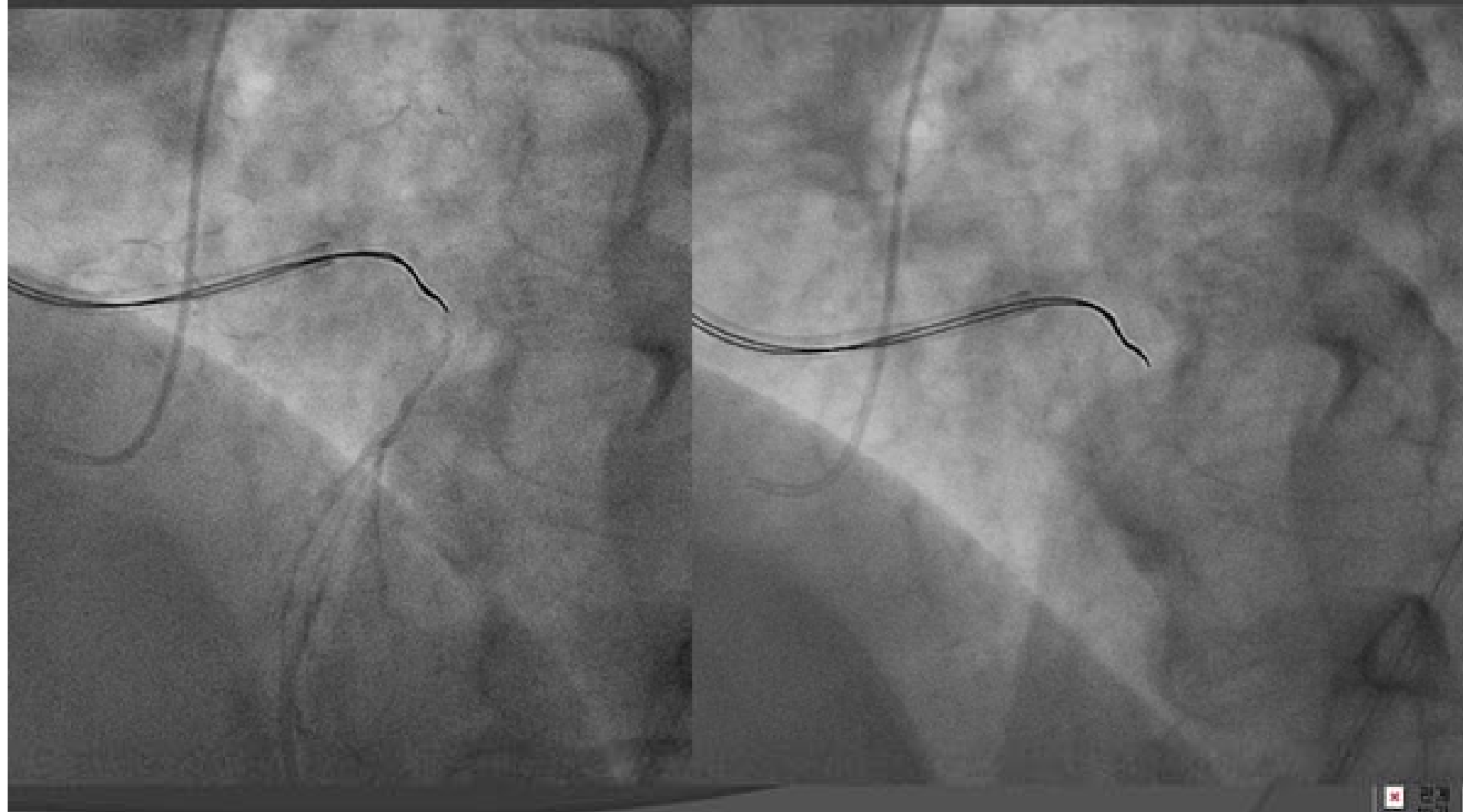


M3G+M12G PARALLEL





M3G+M12G PARALLEL





Exchange through stiff wire to soft wire within the CTO lesion



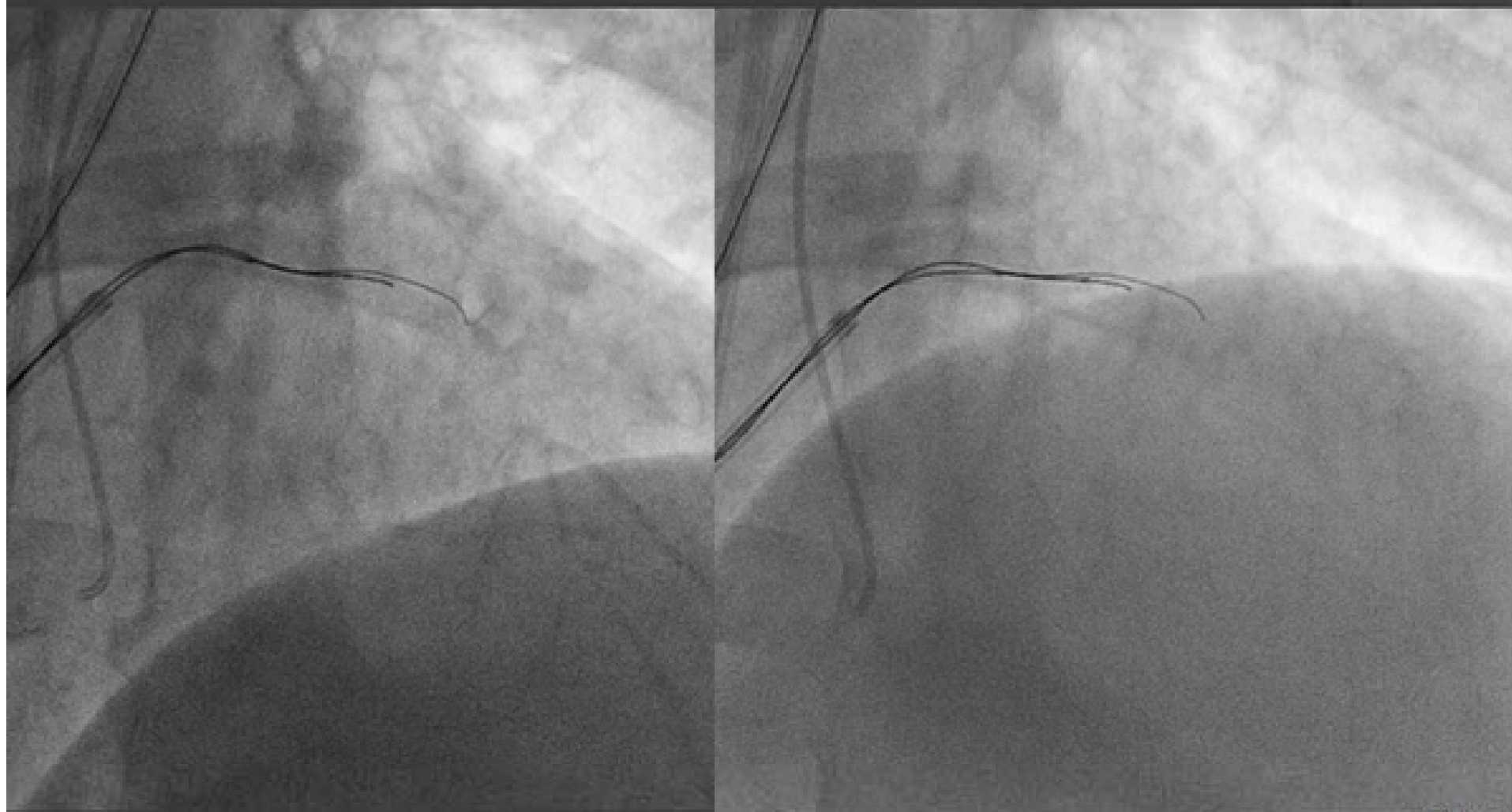
A strong stiff wire such as a Miracle 12g or a Conquest wire is only used for a short distance in CTO lesion.

Strong stiff wire is likely to enter into subintimal space, if used for a long distance in CTO lesion.

The role of strong stiff wire is to cross a proximal hard fibrosis cap. Once a strong stiff wire is entered into the cap, softer wire such as a Xtreme or a Miracle 3g should be used.

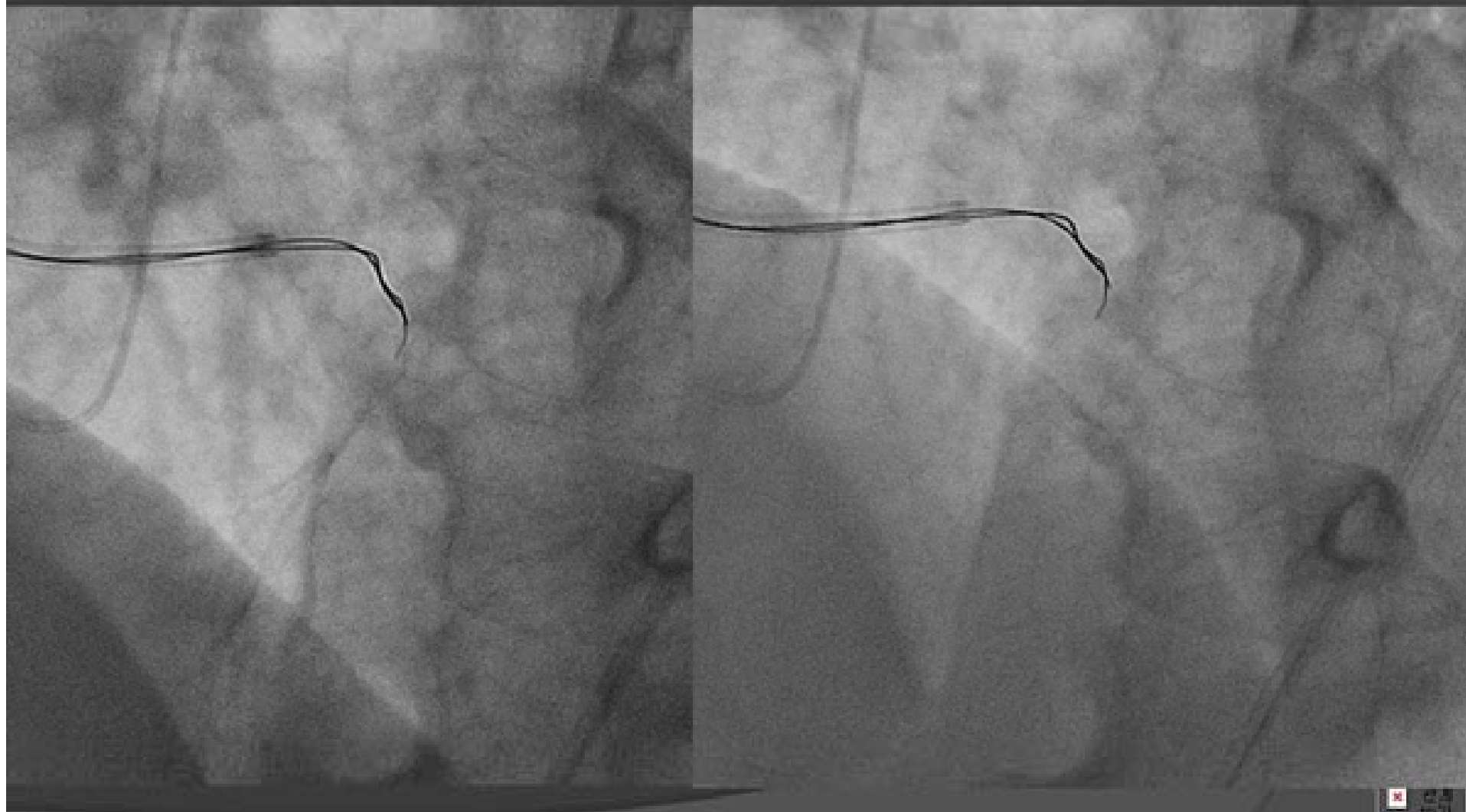


M3G+M12G PARALLEL



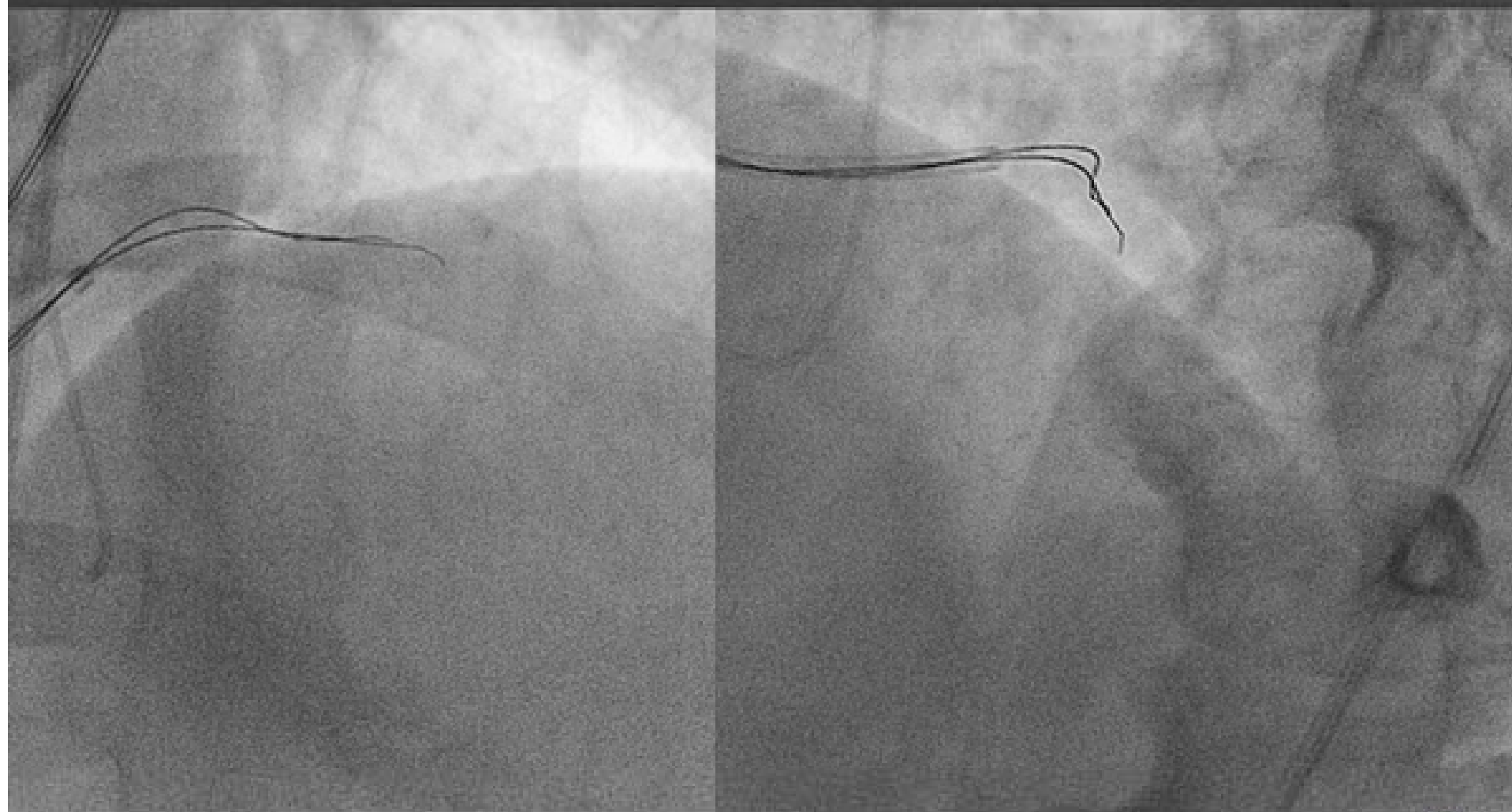


M3G+M12G PARALLEL



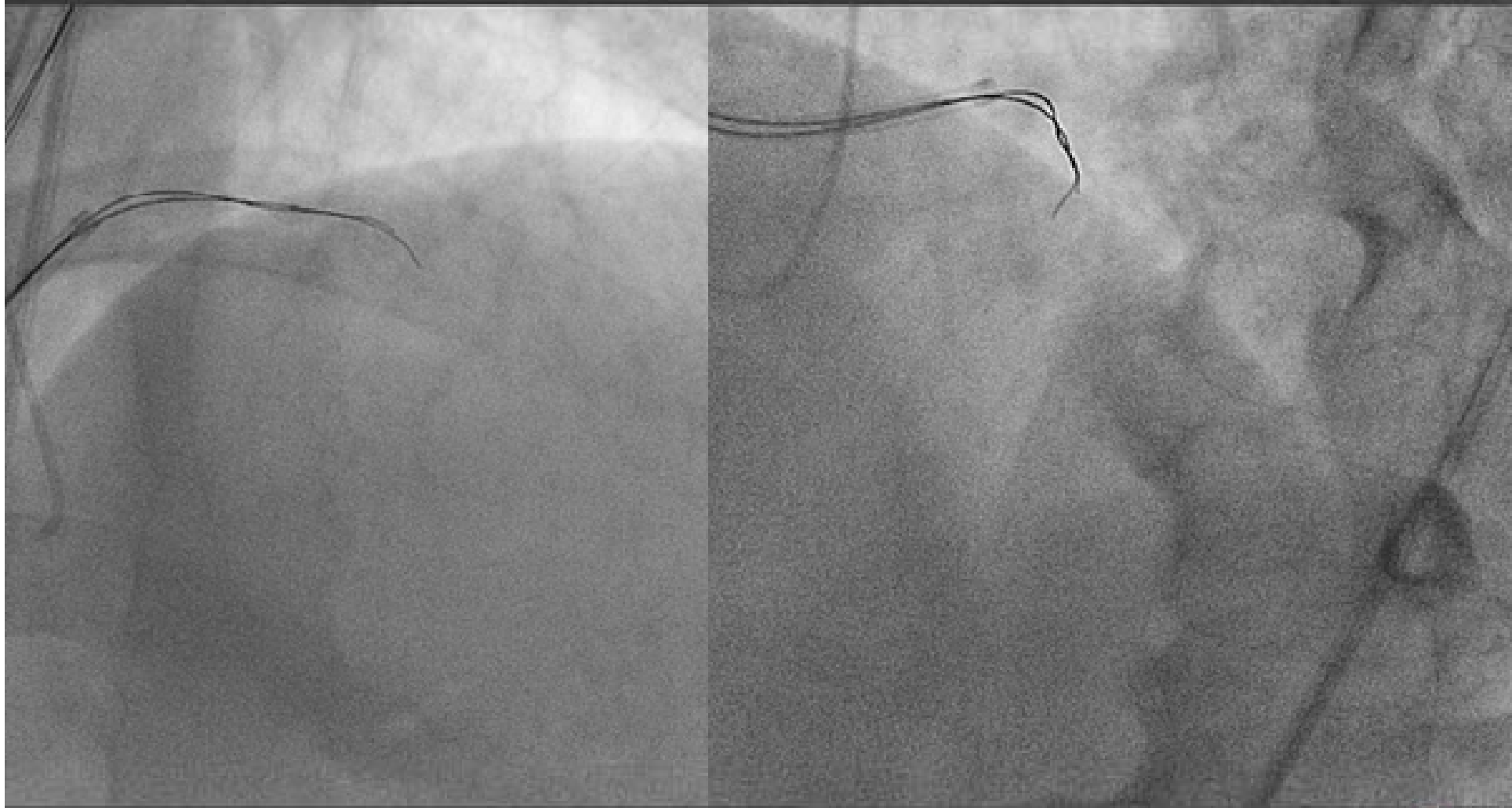


CPR012G+CPR012G PARALLEL



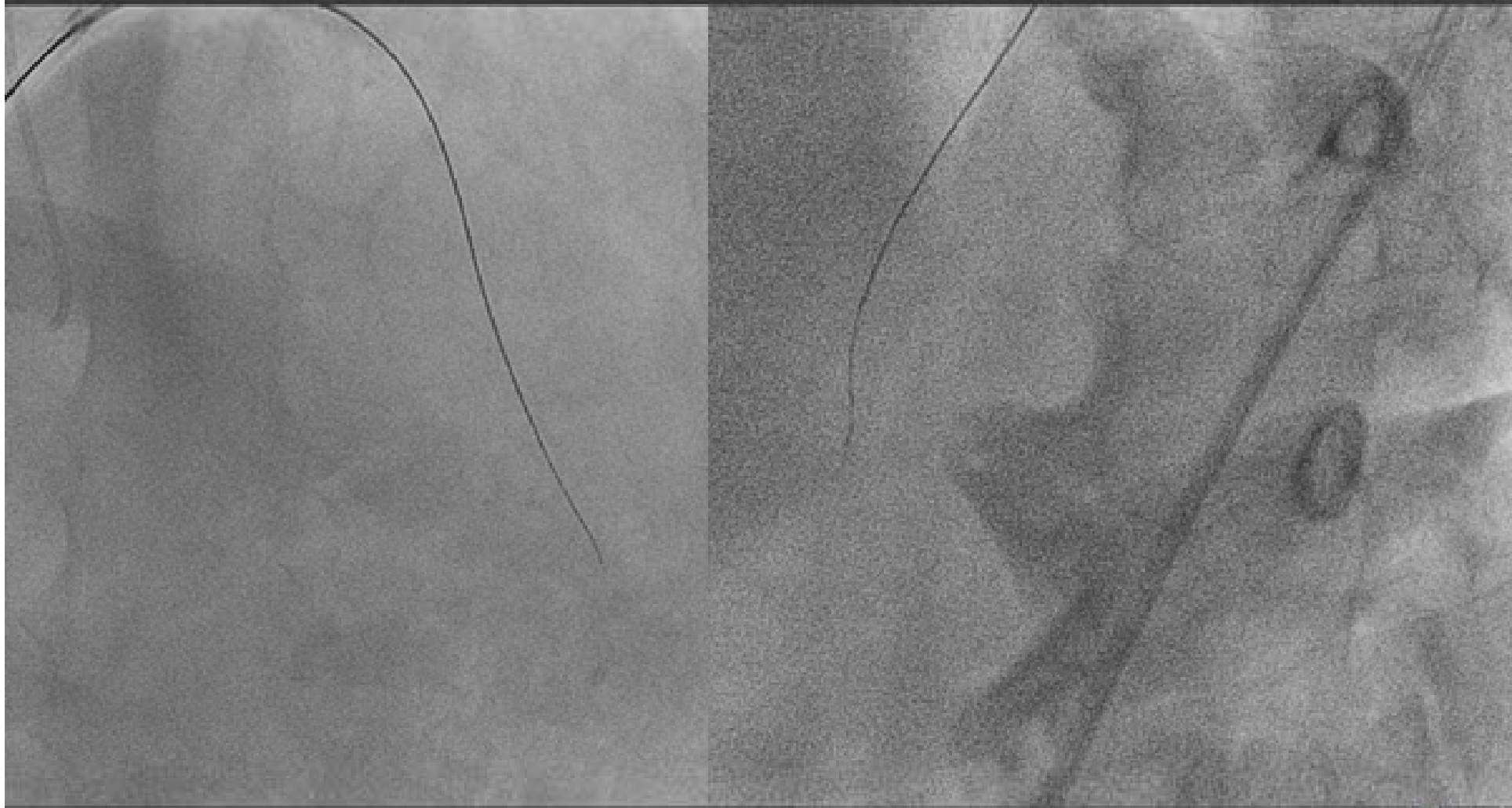


IT CROSSED!!





IT CROSSED!!





Wiring Strategy in Retrograde Approach Era



Pre-procedural Examination of Angiogram w/wo MSCT

Antegrade approach

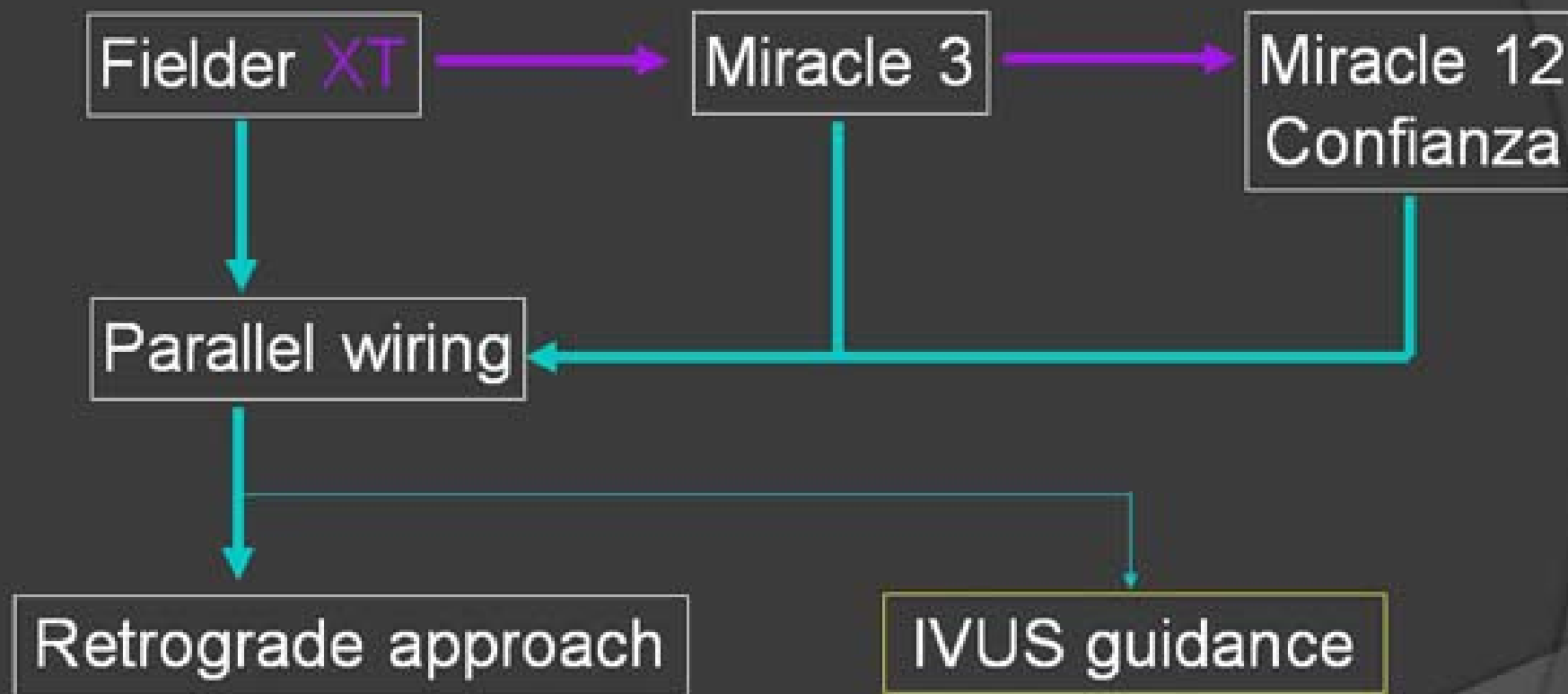
1. Single wire manipulation
2. Parallel wiring
3. IVUS guided wiring

Retrograde approach

1. Wiring through collateral
2. Retrograde wiring
 - Retrograde wire crossing
 - Kissing wire technique
 - Knuckle wire technique
 - CART
 - Reverse CART



Current CTO Wiring Strategy



————— *Unsuccess
(Not advanced)*

————— *Failure
(Subintimal tracking)*



Current Wiring Technique for Coronary CTO



IVUS guided wiring technique

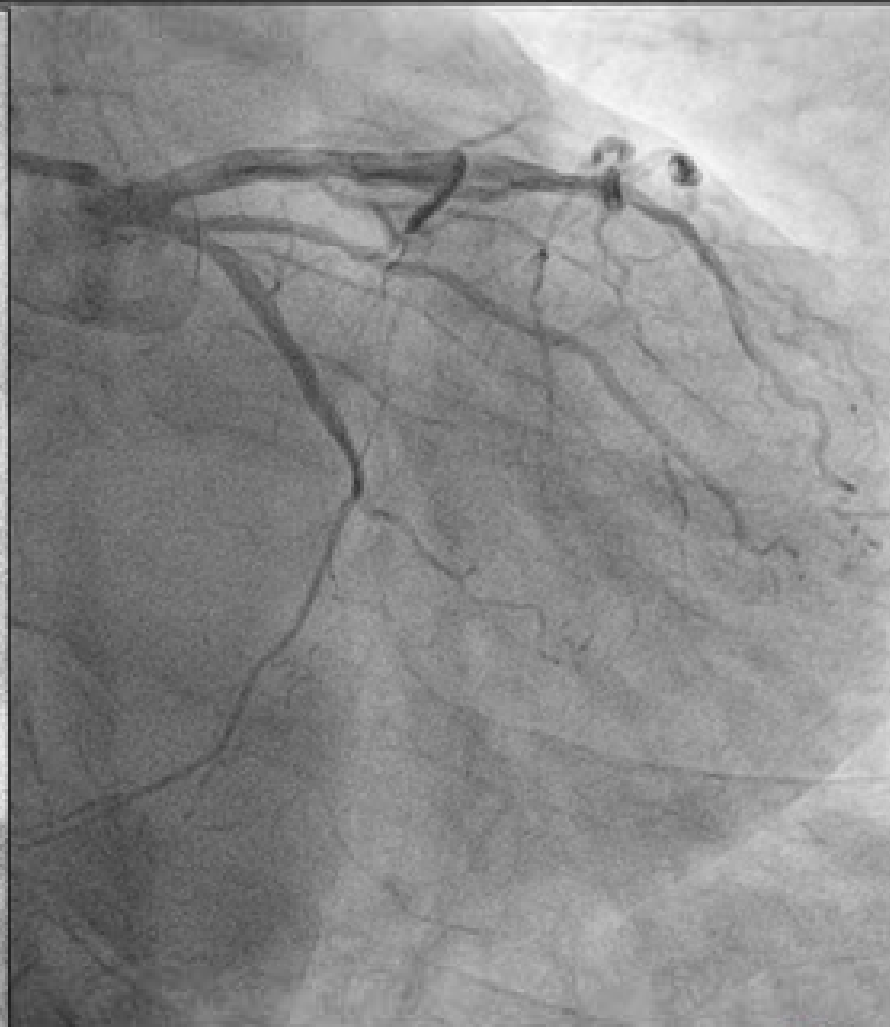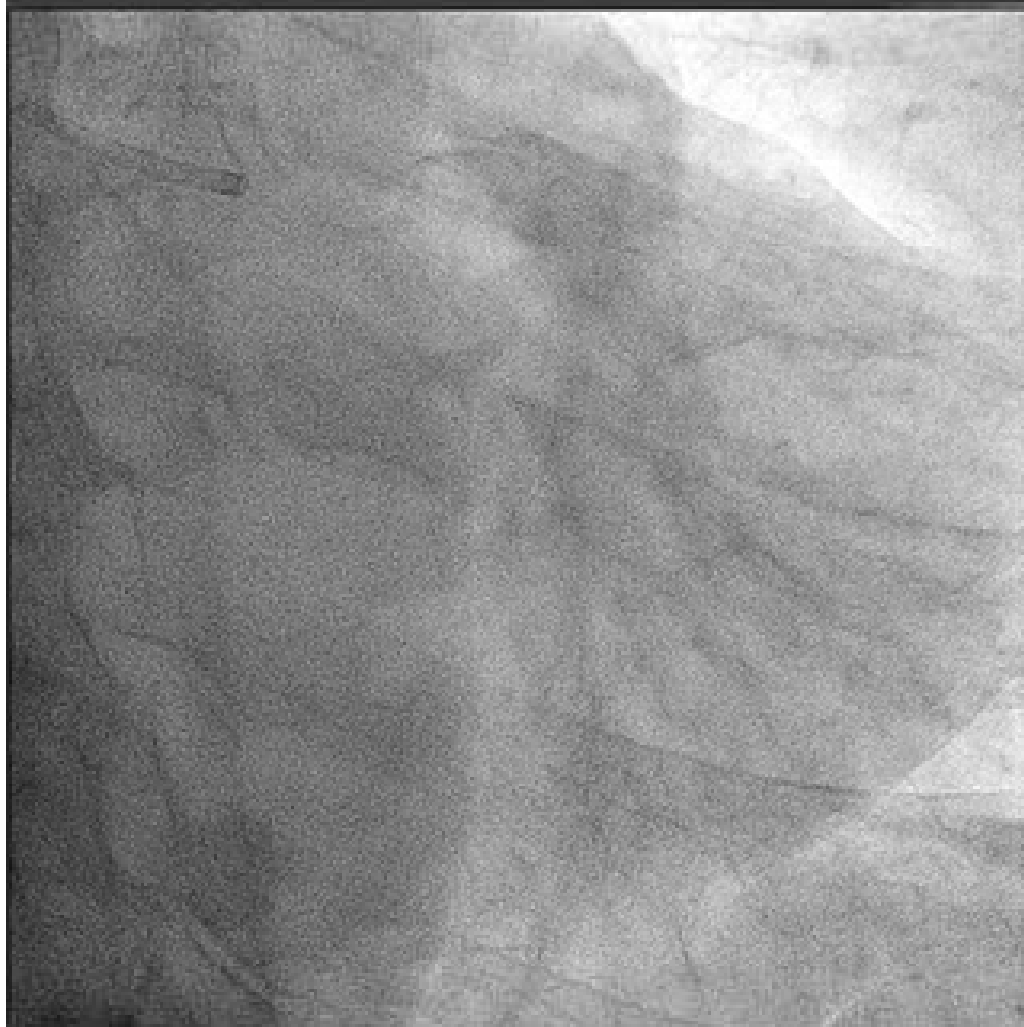- A. Confirmation of the entrance of CTO and entry point of the wire
- B. Penetration from subintimal space to true lumen



THE ENTRANCE OF CTO AND ENTRY POINT OF THE WIRE

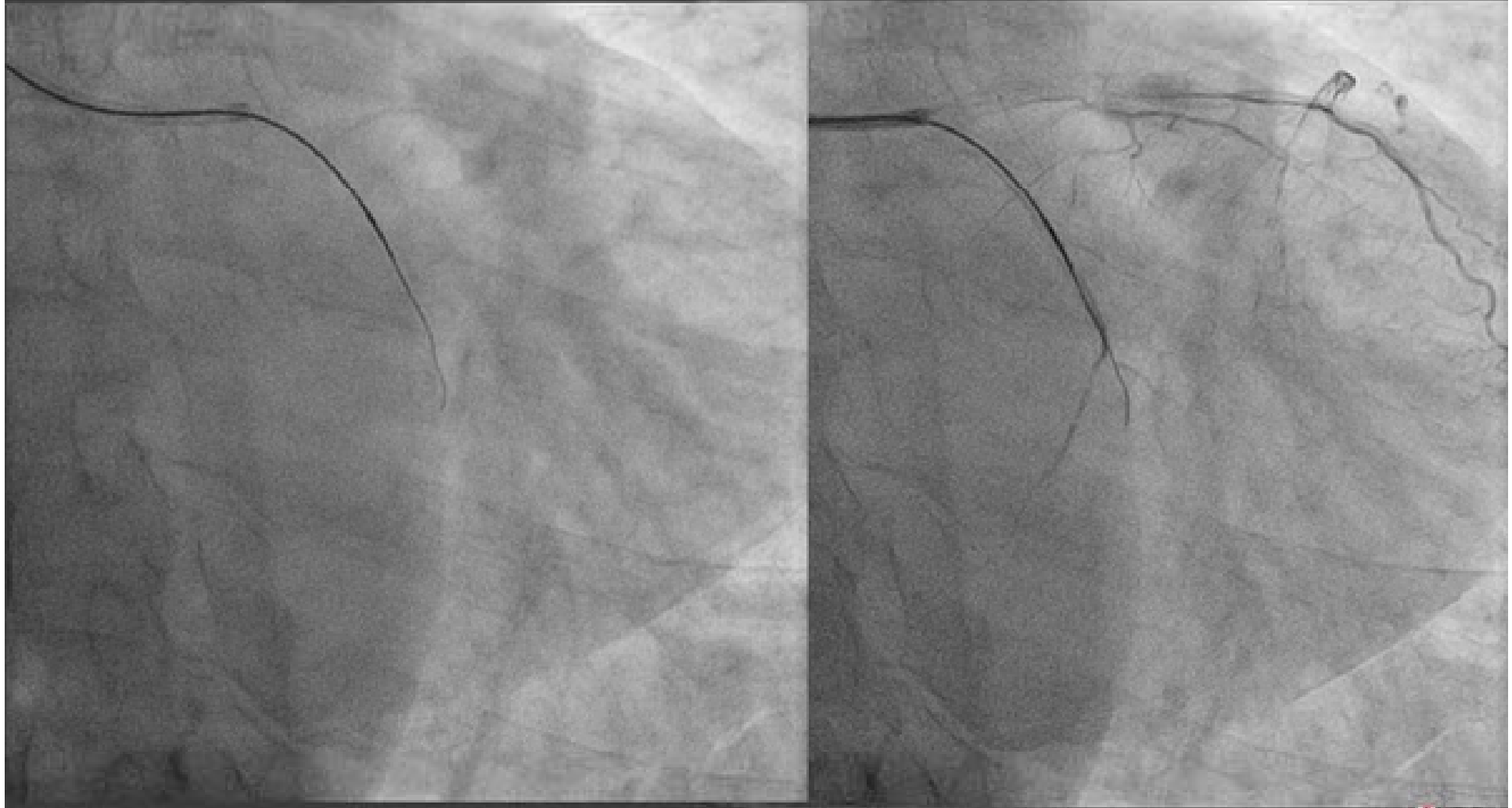


LCx Subtotal



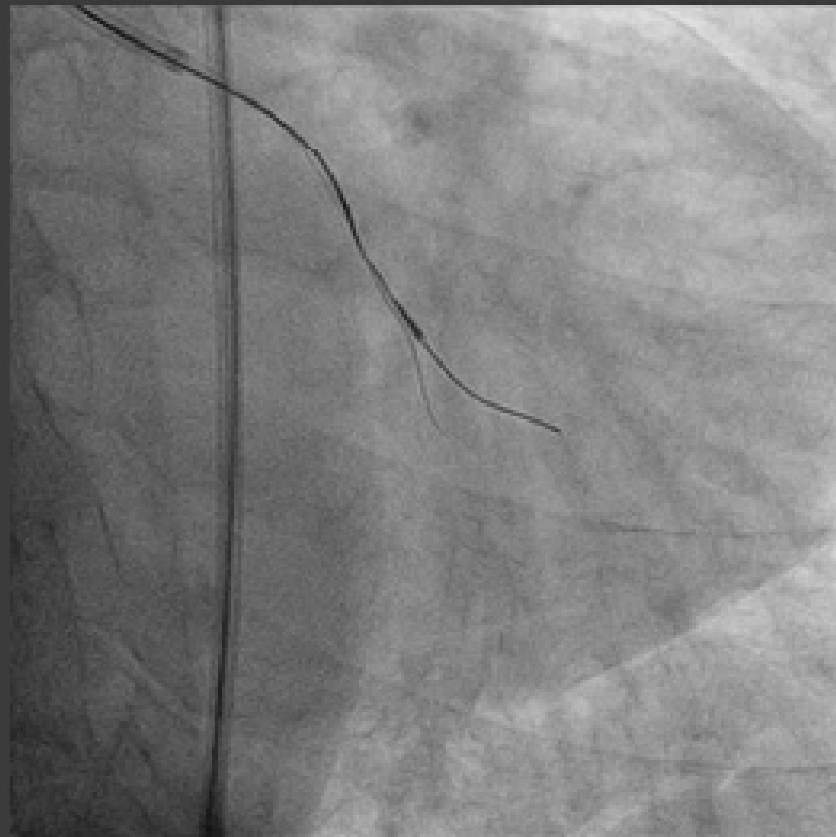


Corsair+FielderXT(TRI)



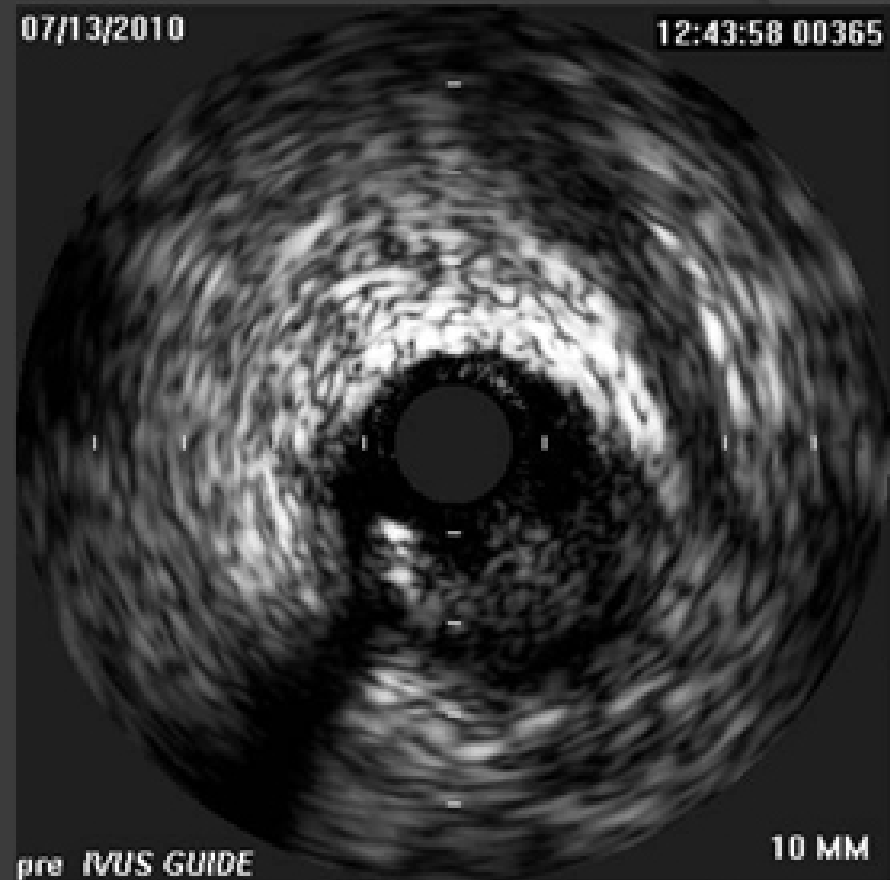

IVUS Guided (TFI)



07/13/2010

12:43:58 00365

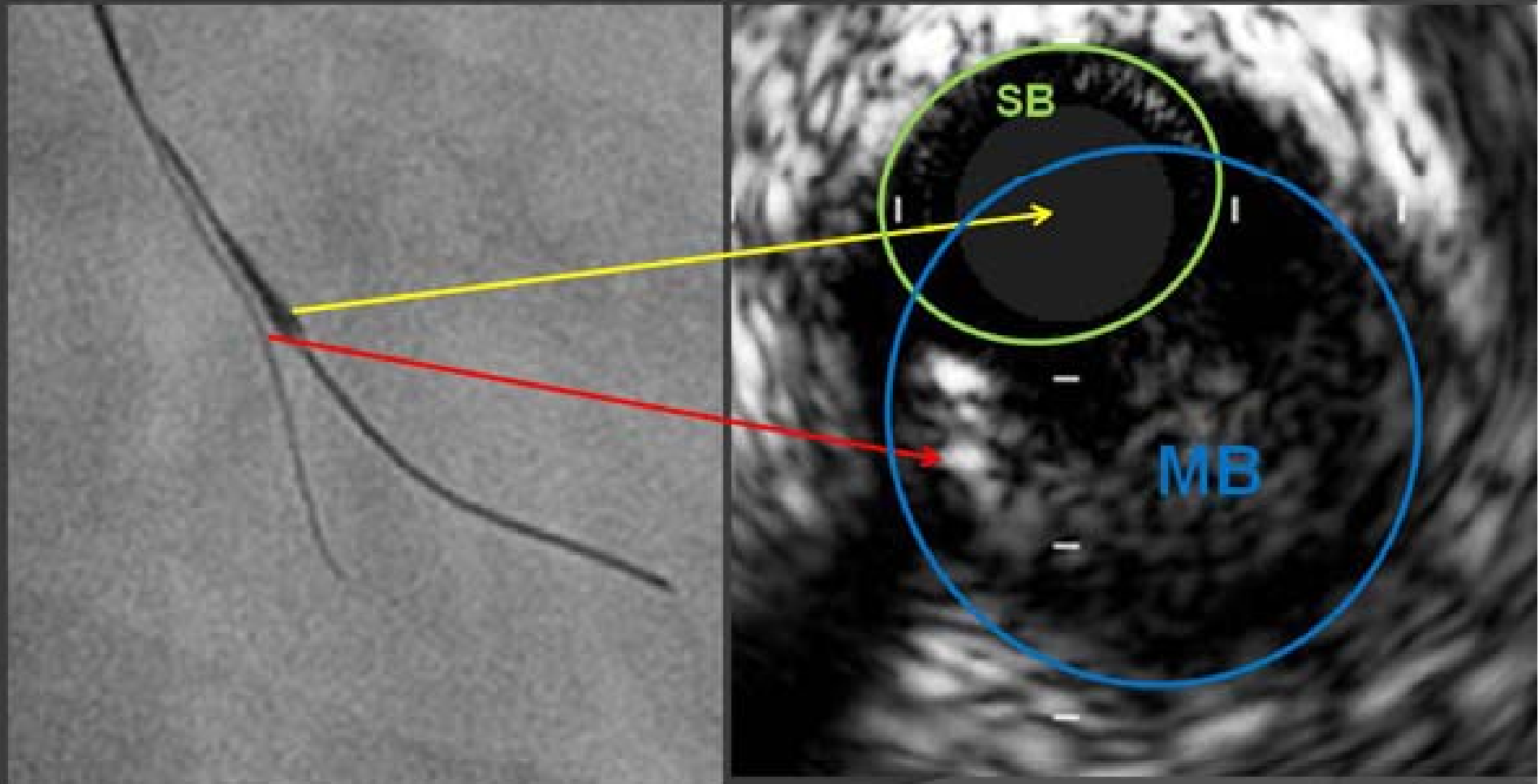


pre IVUS GUIDE

10 MM

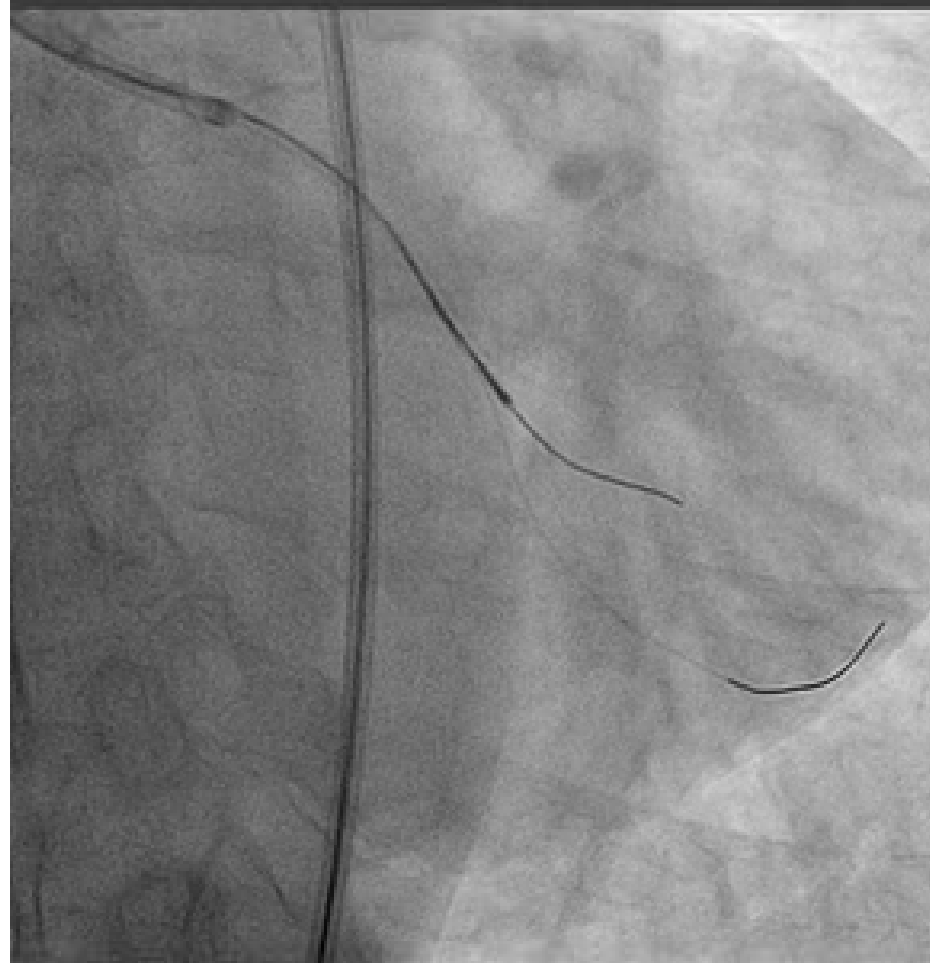


Wire in Sub?





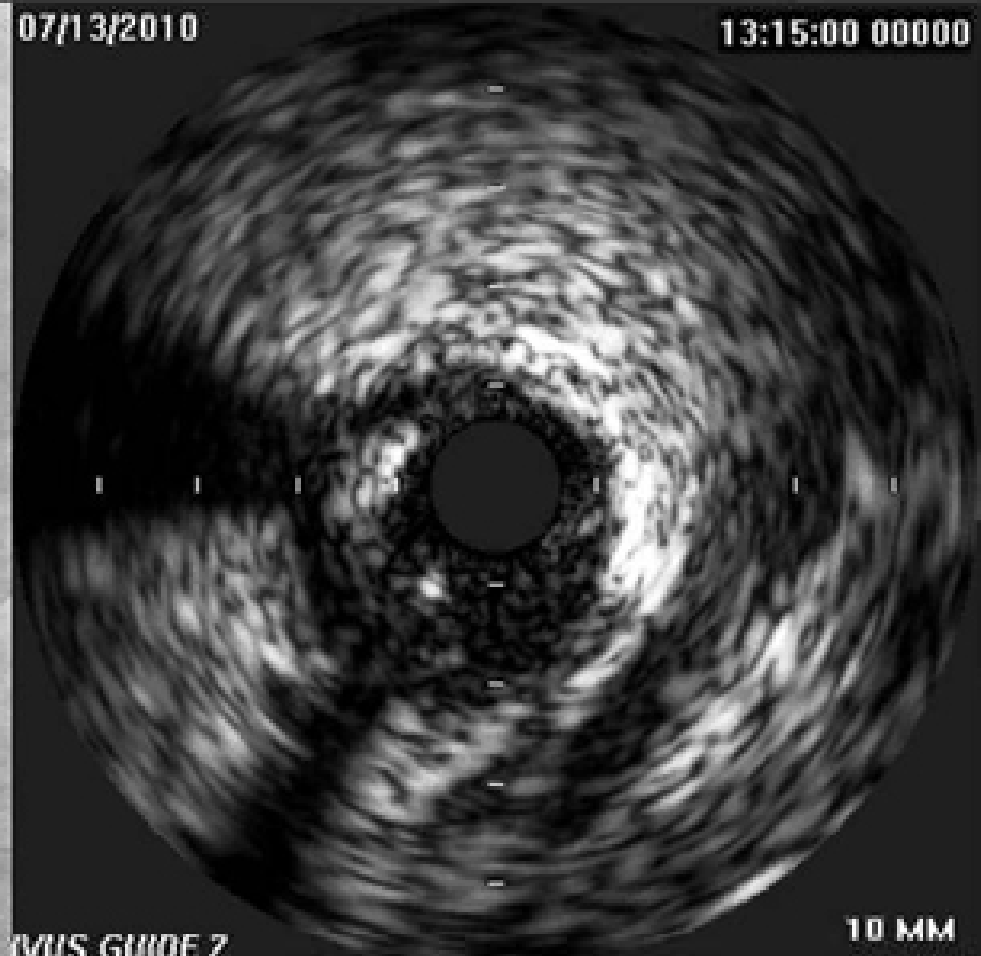IVUS Guided (TFI)



07/13/2010

13:15:00 00000

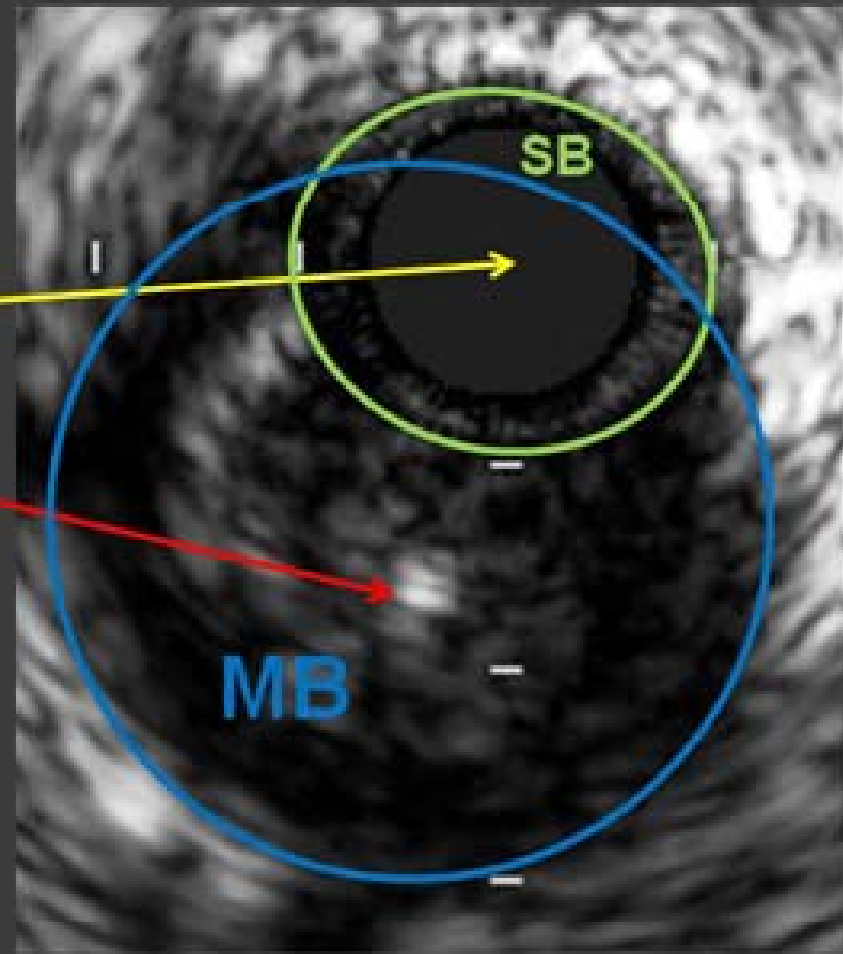
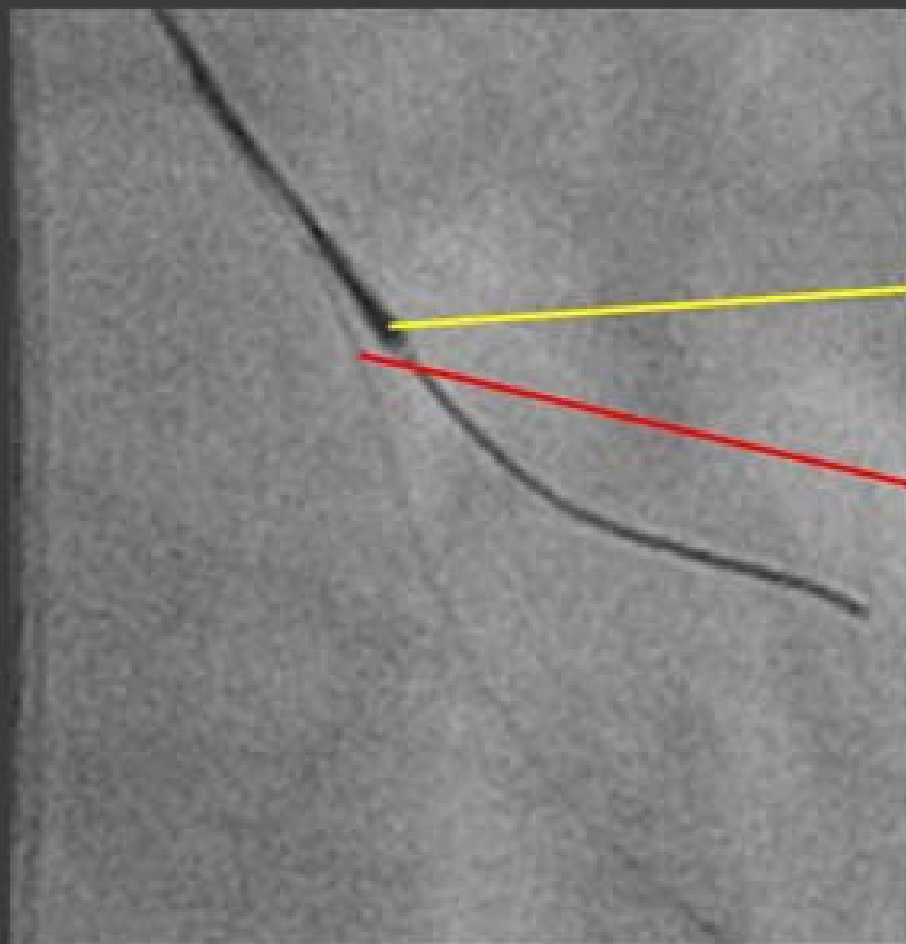
IVUS GUIDE 2



10 MM

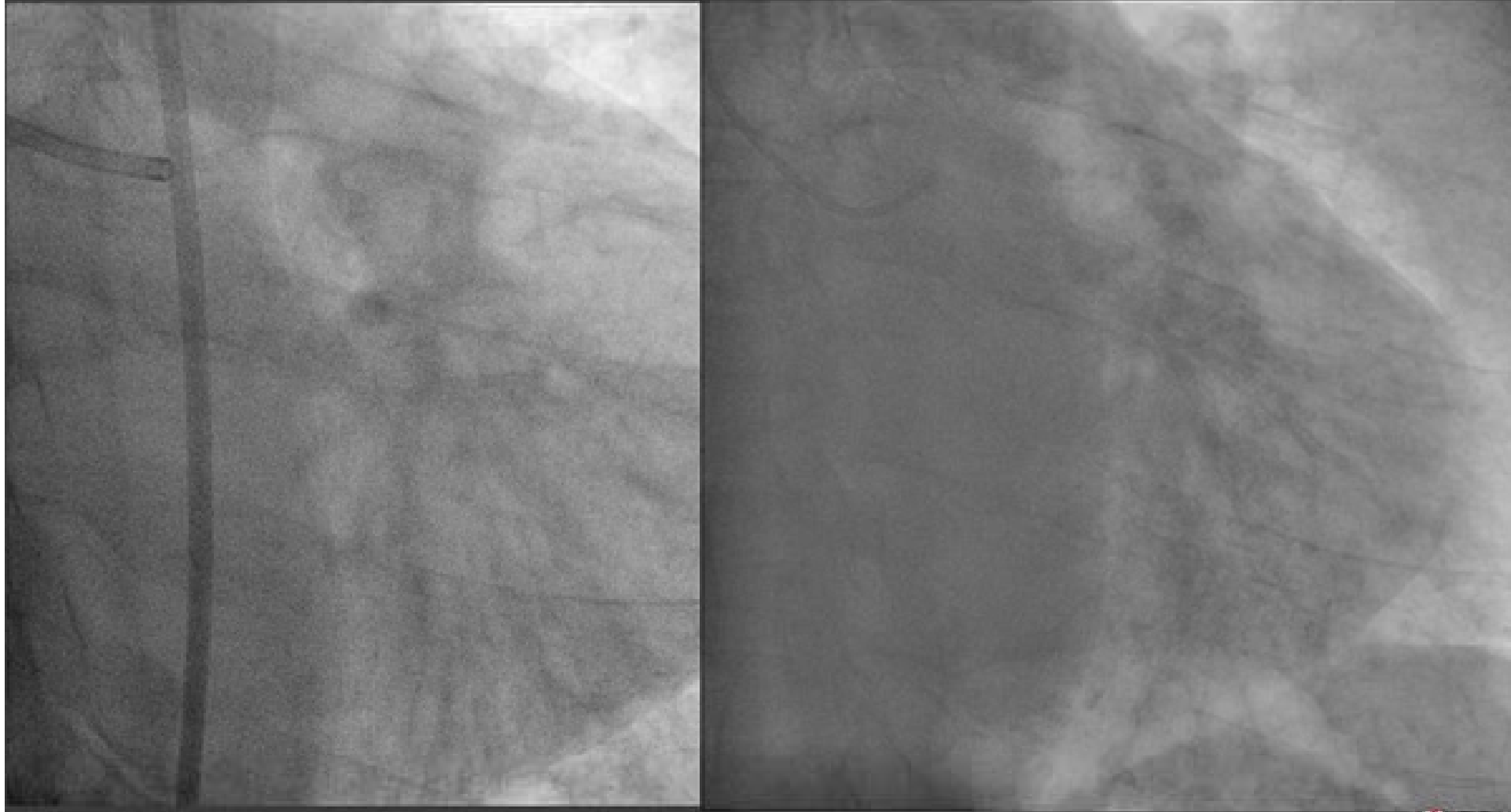


Wire in True!



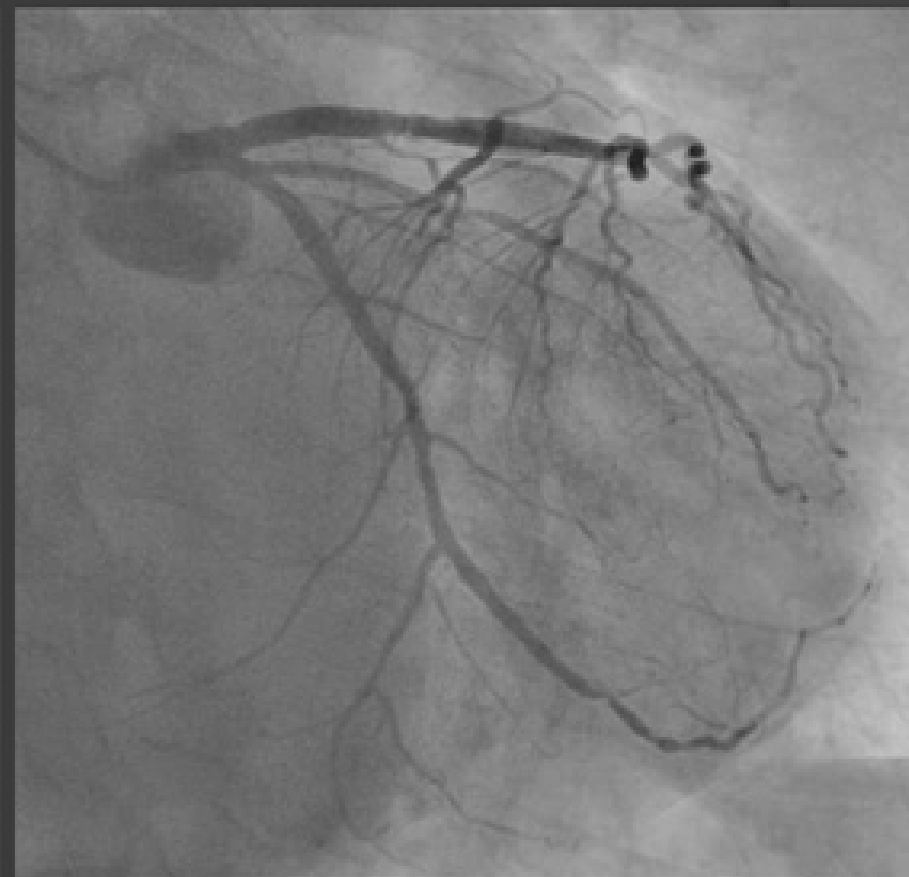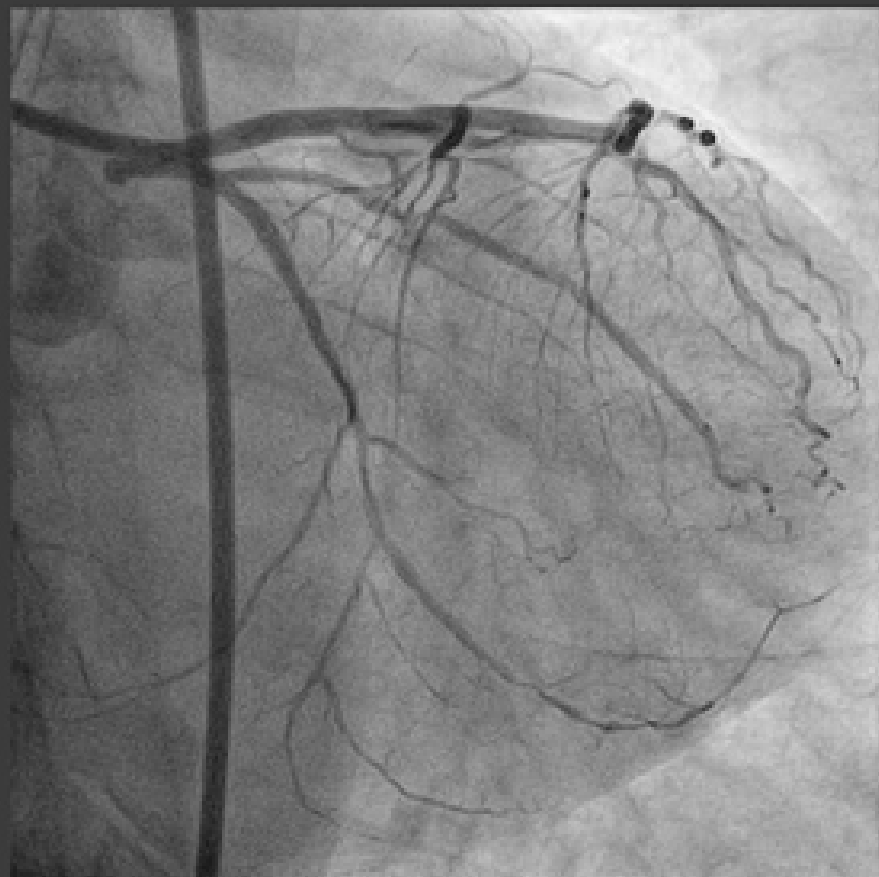


Final & Follow Up





Final & Follow Up

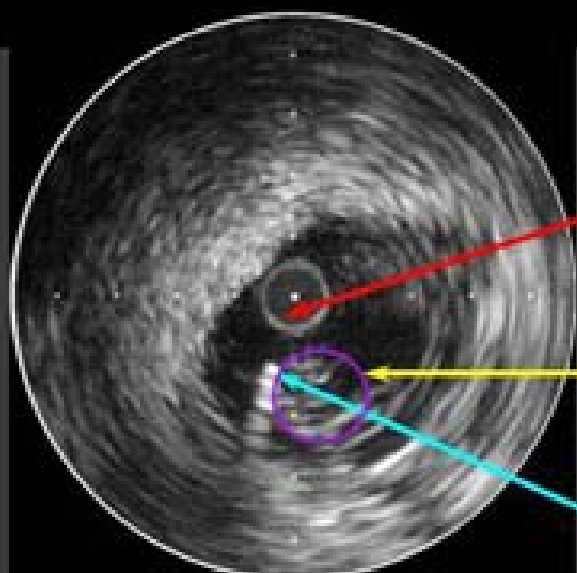
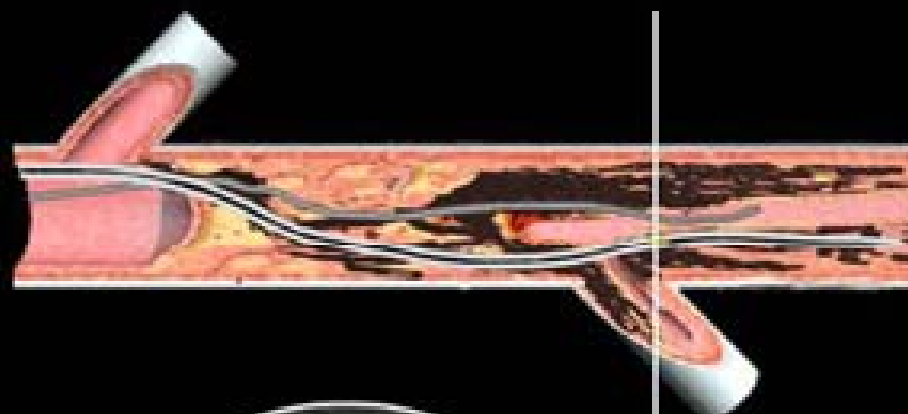
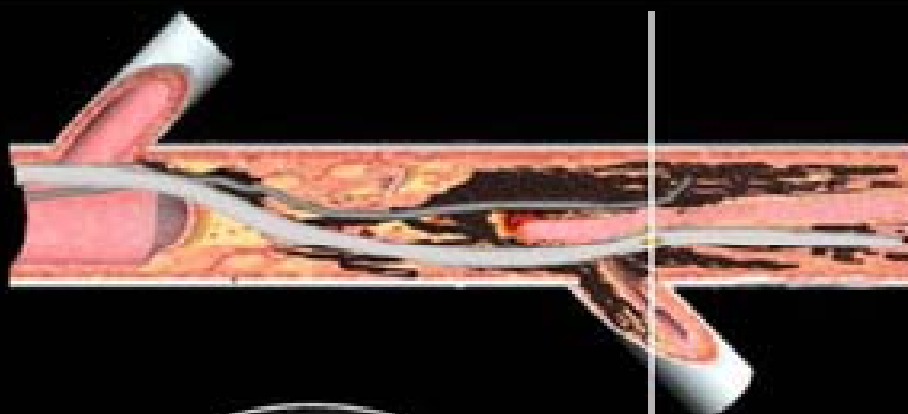



PENETRATION FROM SUBINTIMAL SPACE TO TRUE LUMEN



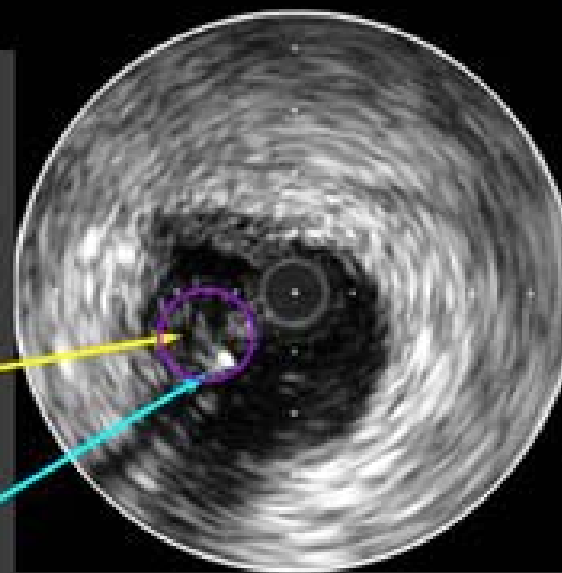
IVUS guided wiring technique



False lumen

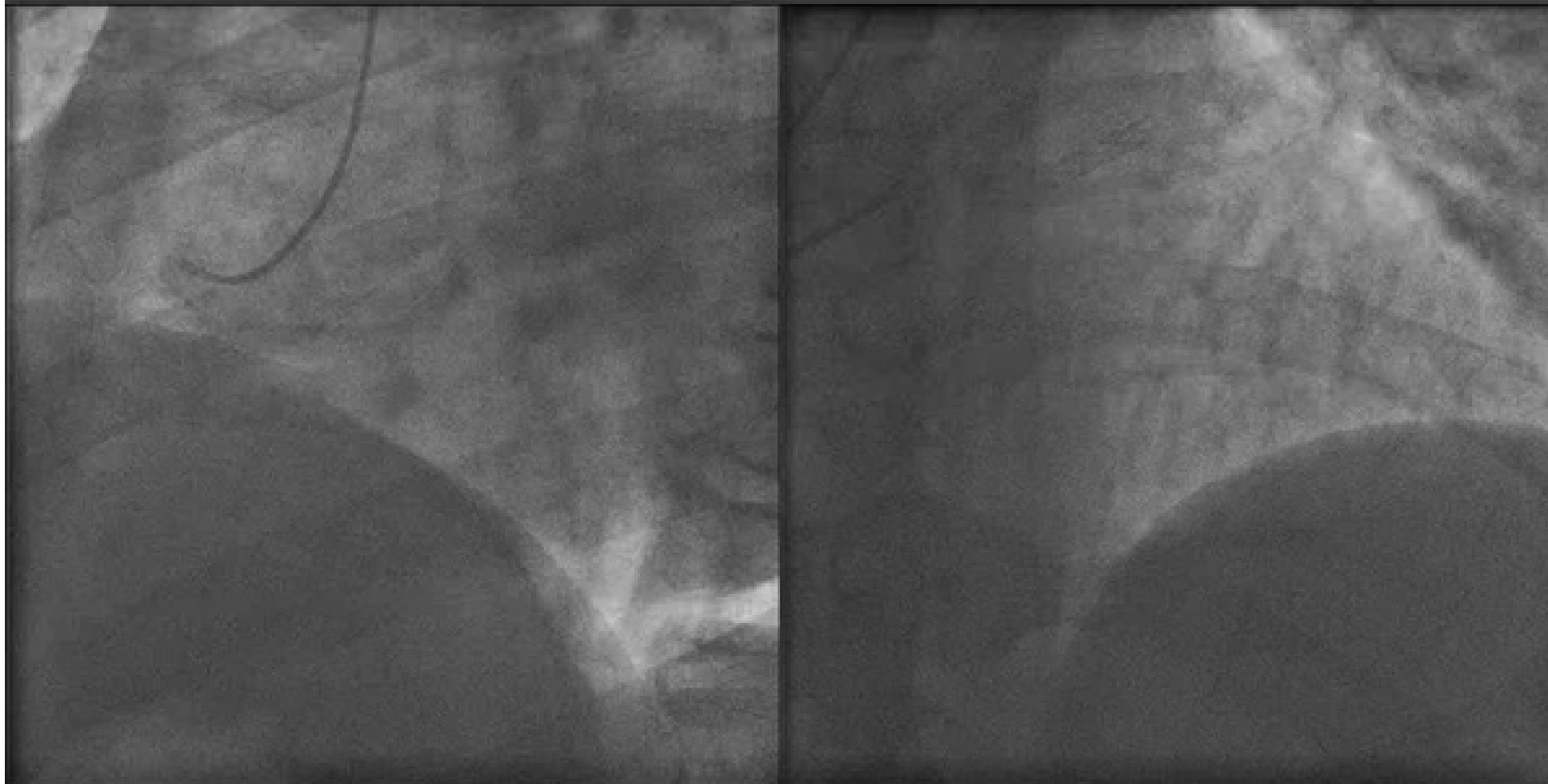
True lumen

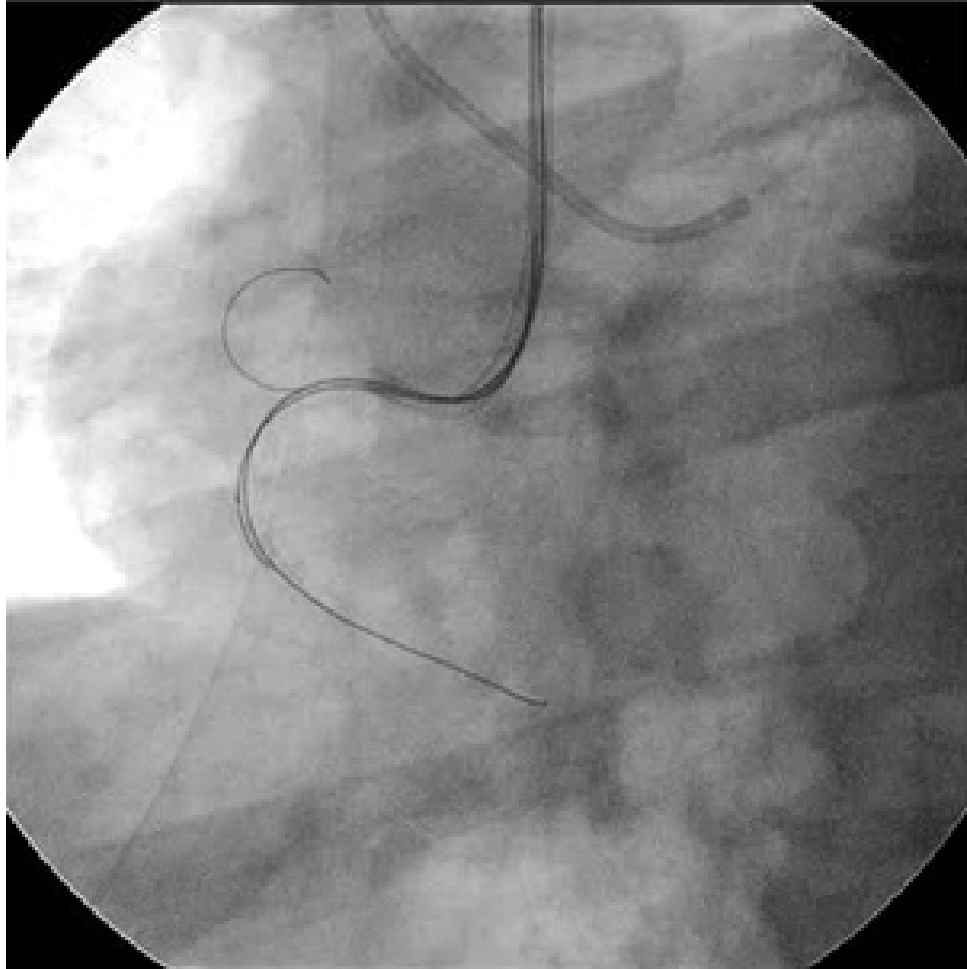
Guide wire



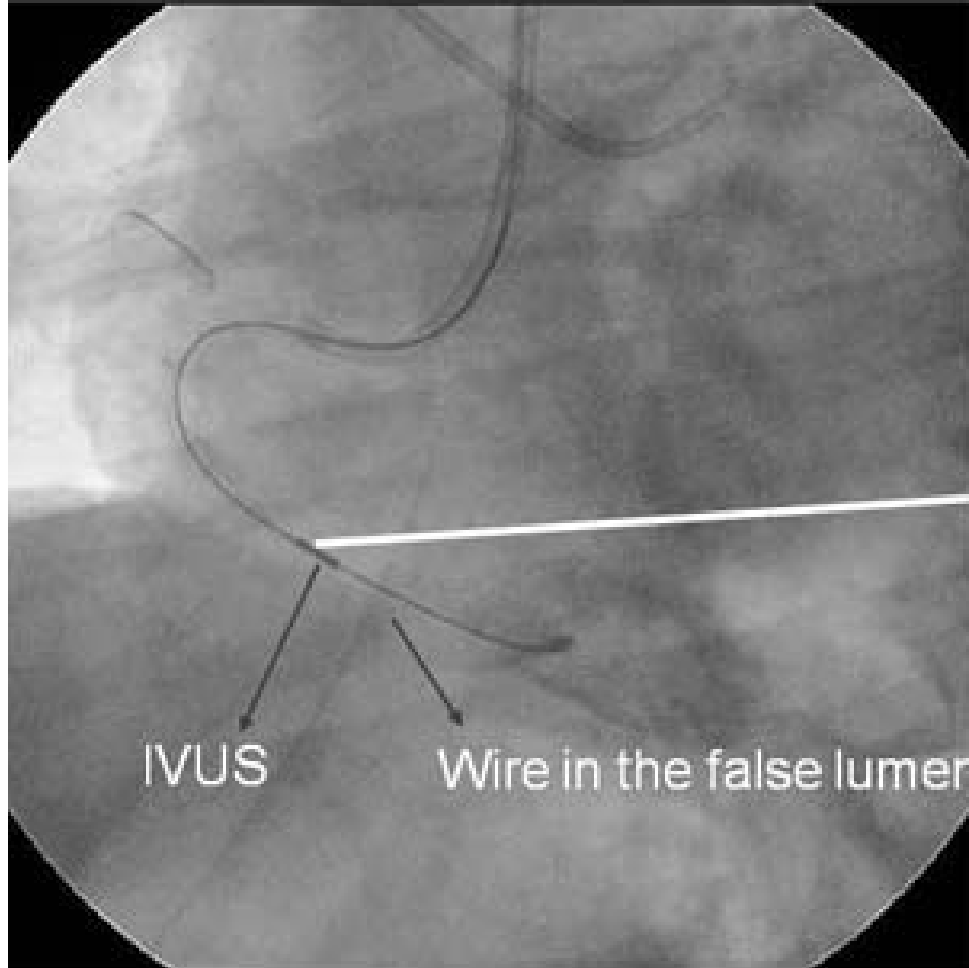


Case: RCA-CTO





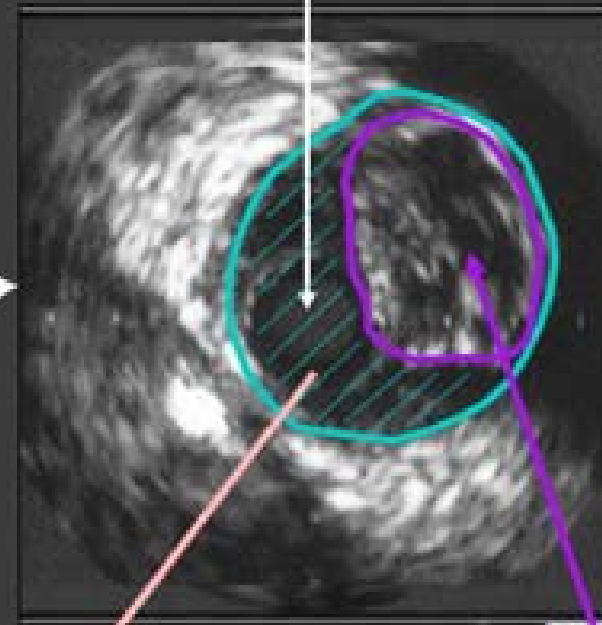
MIRACLEbros 12 with Confianza



IVUS

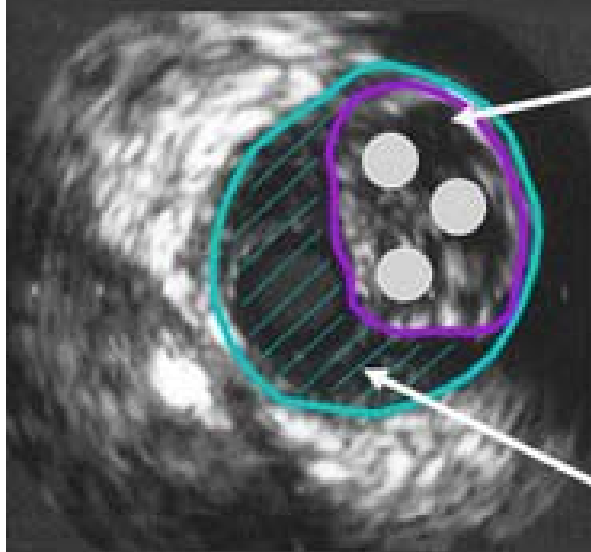
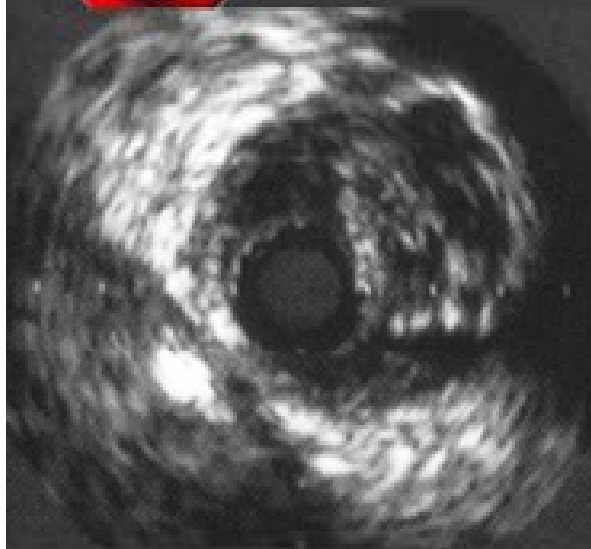
Wire in the false lumen

IVUS catheter



False lumen

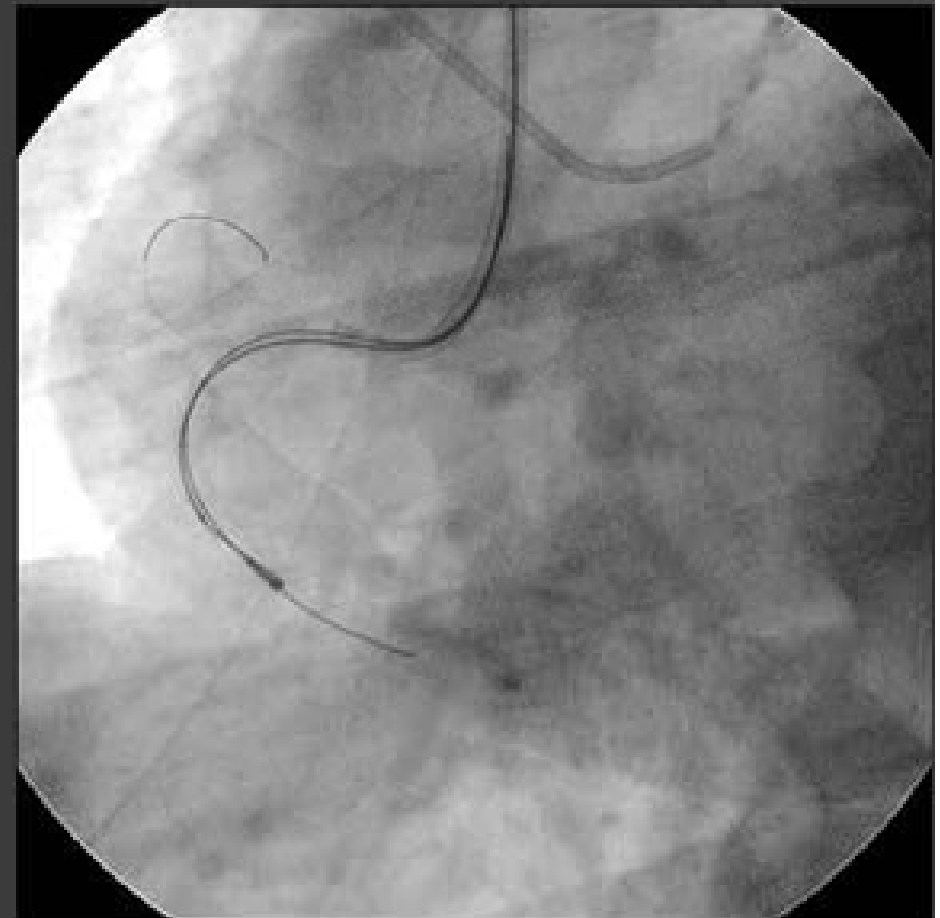
True lumen



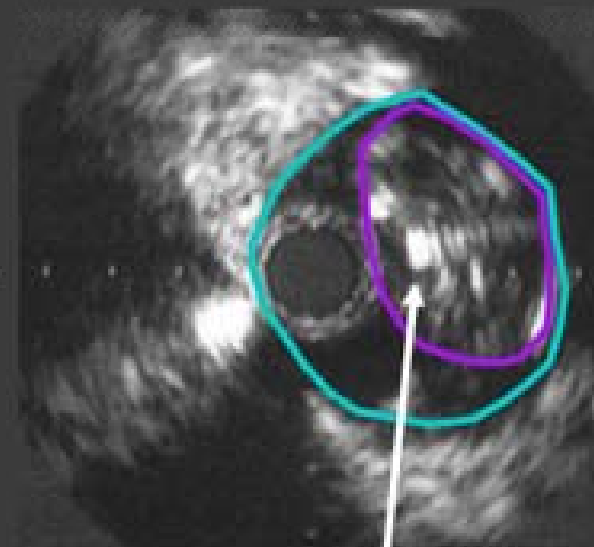
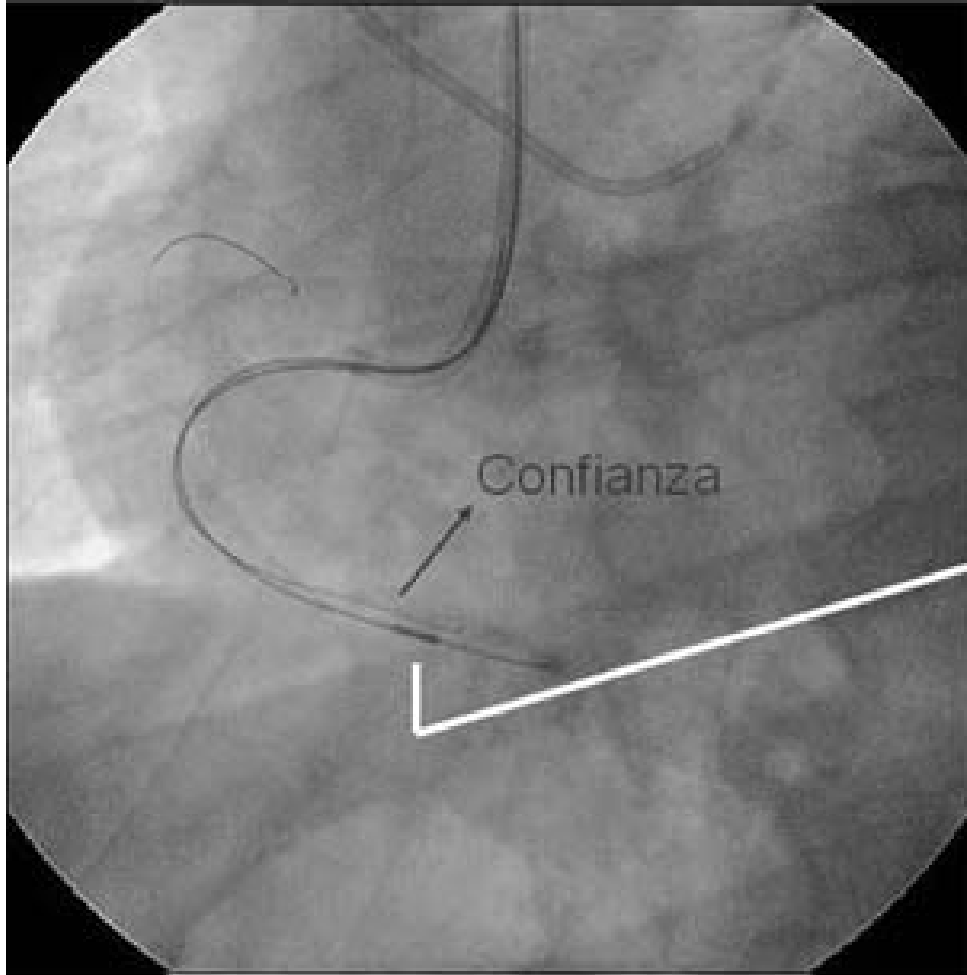
True lumen

● 2nd wire

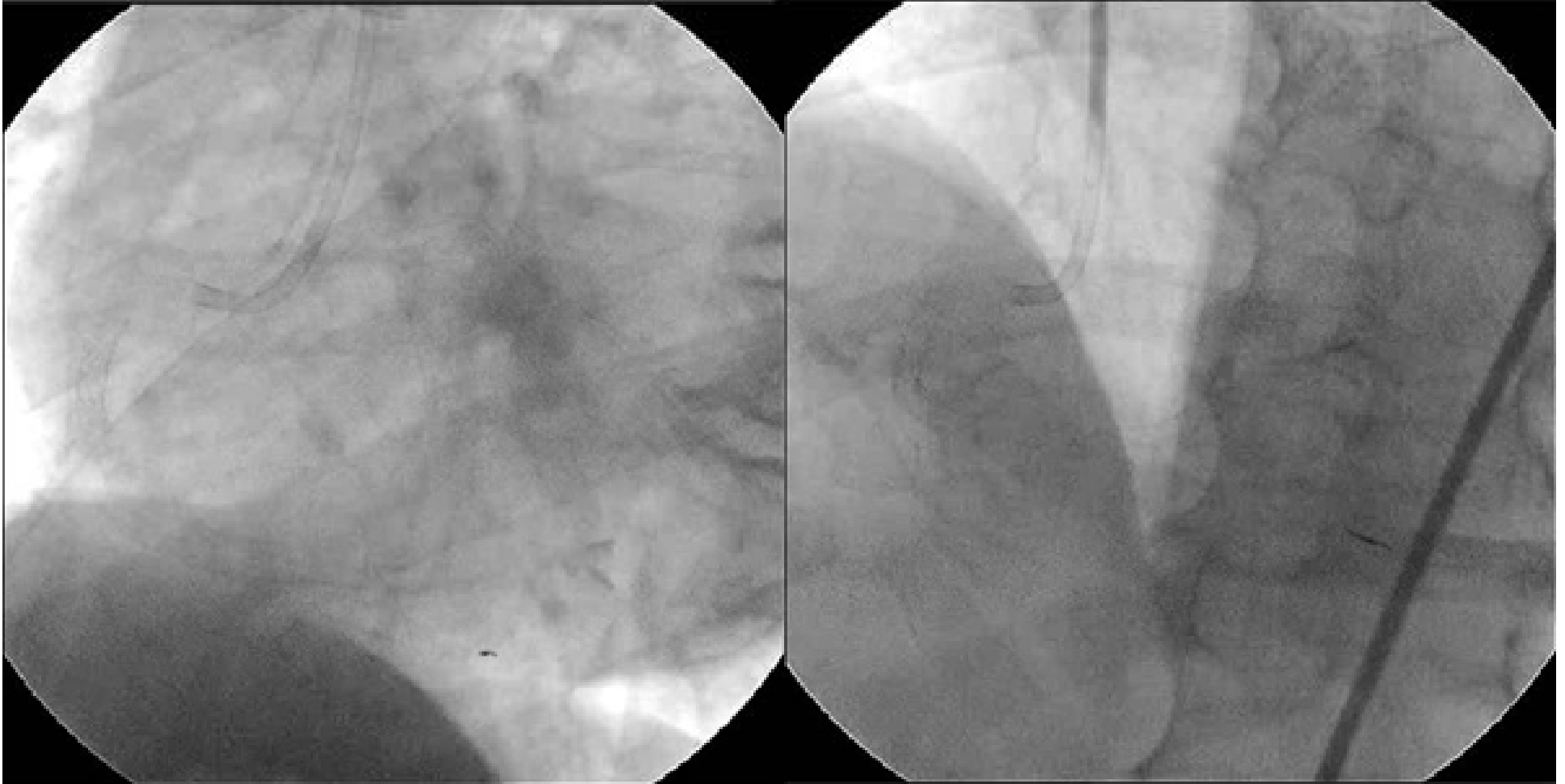False lumen



Confianza with IVUS



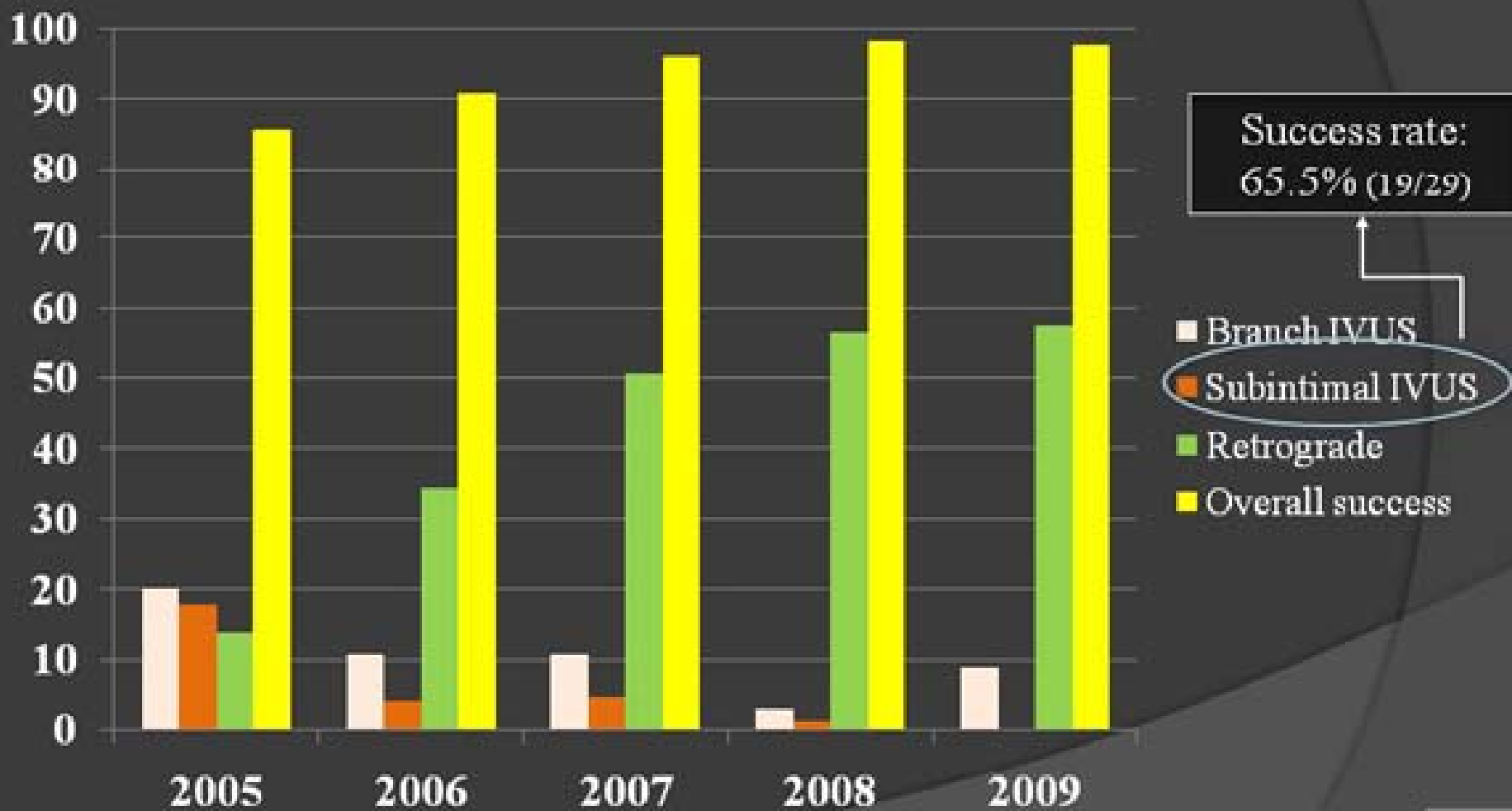
2nd Guide wire
Confianza





Impact of IVUS Guidance on Overall Success Rate

(%)





HI-TORQUE PROGRESS



Polymer and Tapered Coil Tip HYBRID Guide Wire

TAPERED TIP
0.012", 0.0105"

POLYMER Sleeve with HYDROPHILIC COATING:
Designed to maximize wire maneuverability while in the lesion



BARE COIL:
For tactile feel in the lesion

PARABOLIC CORE:
Transition less parabolic core designed excellent steering and control.

CORE-TO-TIP STAINLESS STEEL

Non-coating 2mm*
For stabilizing tip control

3cm RADIOPAQUE COIL



Tip diameter

0.012"



	Tip Load (g)	Penetration Power (kg/in ²)
HT PROGRESS 40	4.8	40
HT PROGRESS 80	9.7	80
HT PROGRESS 120	13.9	120

Tip diameter

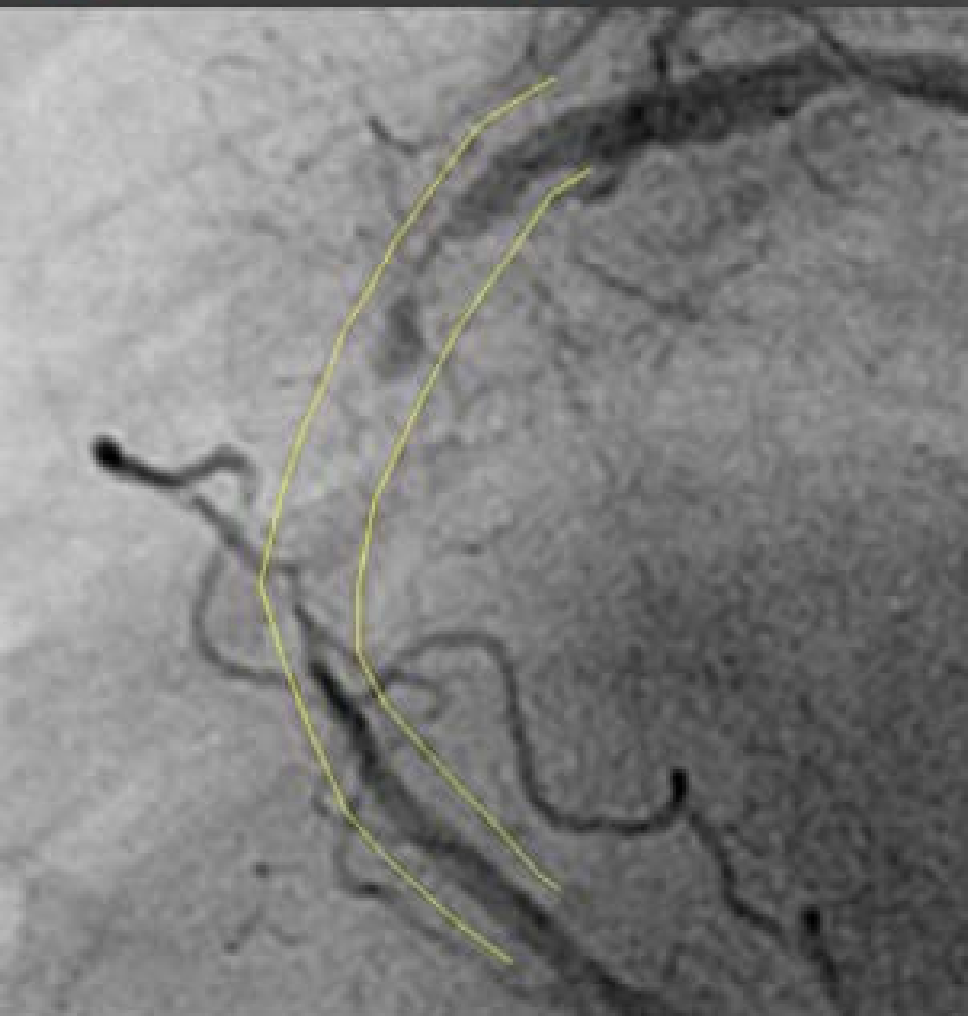
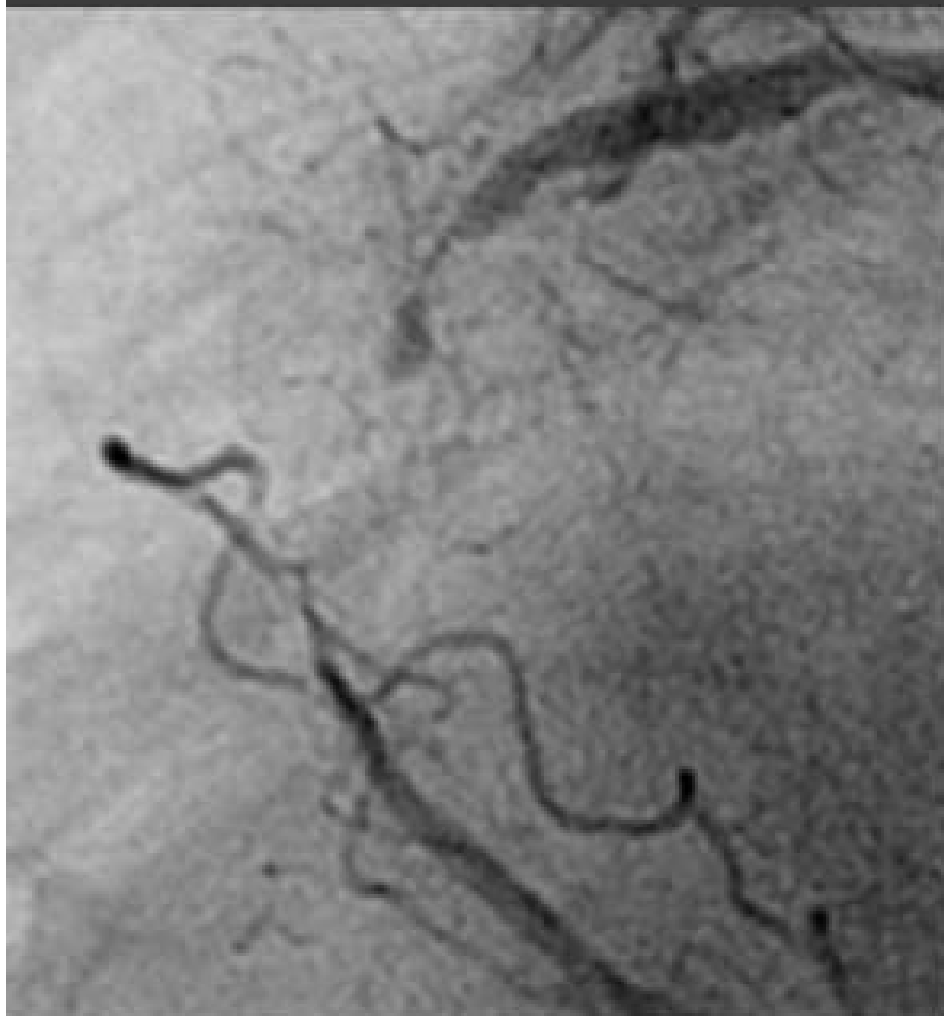0.0105"



	Tip Load (g)	Penetration Power (kg/in ²)
HT PROGRESS 140T	12.5	140

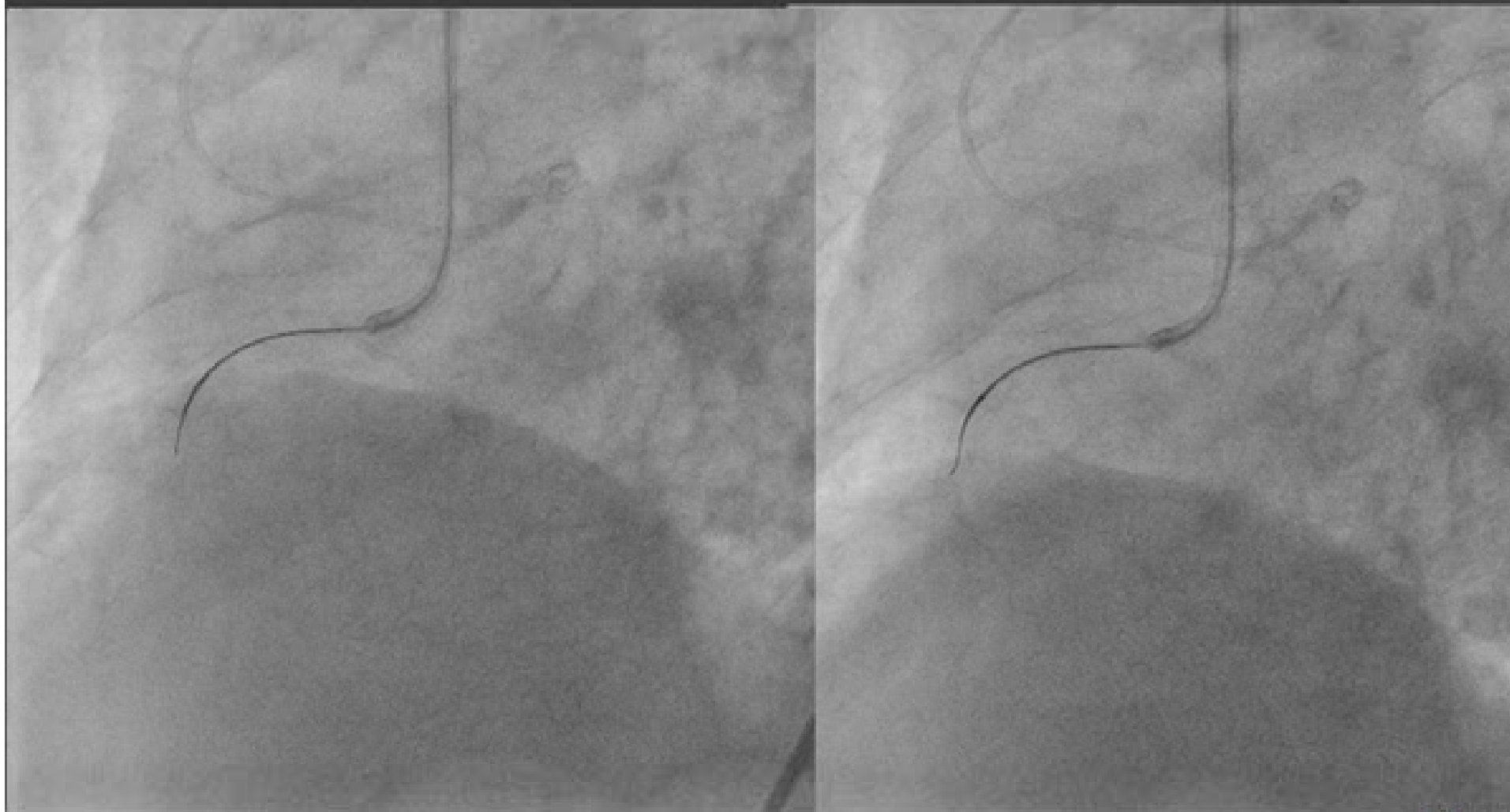


RCA CTO (In stent)



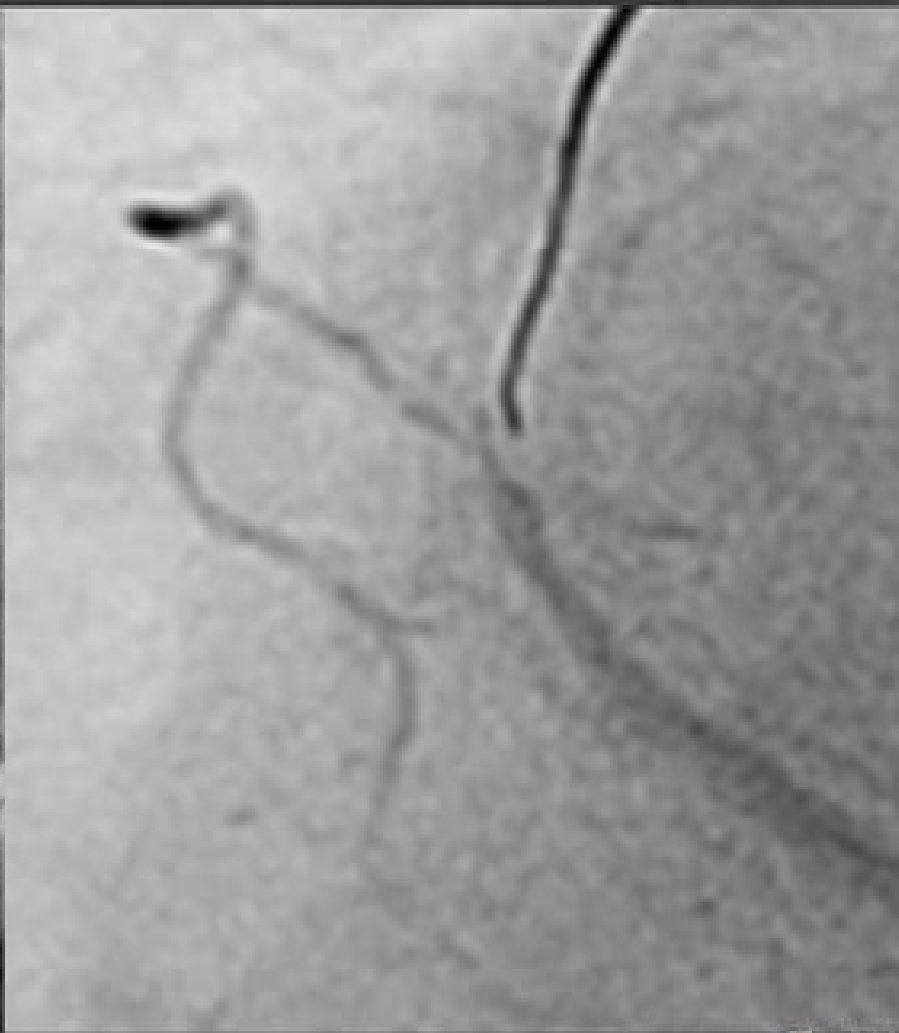
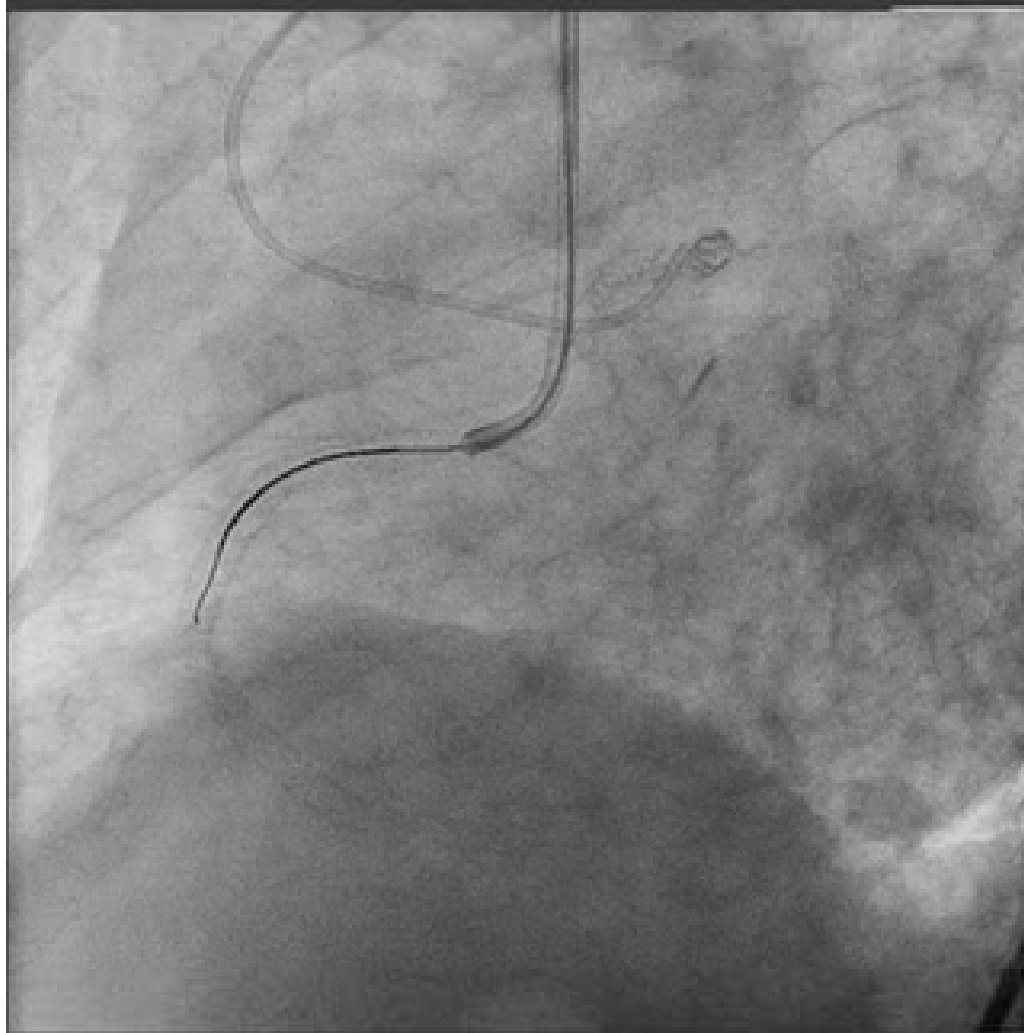


Corsair + Progress 40



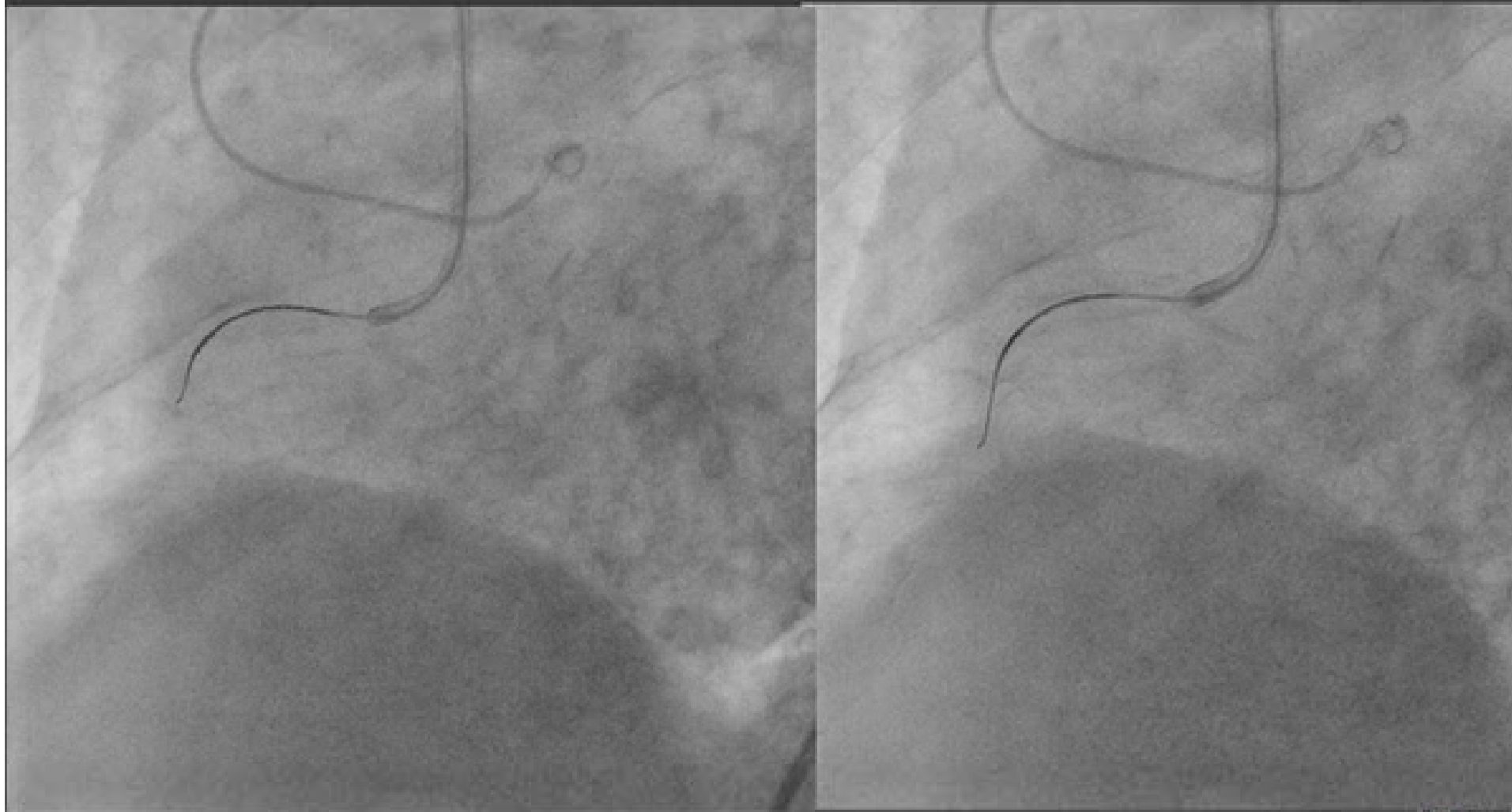


Not in distal true lumen...





Passed with Progress40





Corsair in the Antegrade Approach




As A Support Catheter for Wiring

- Equivalent wire maneuverability as conventional MC
- Good cross-ability of the tip into the occlusion

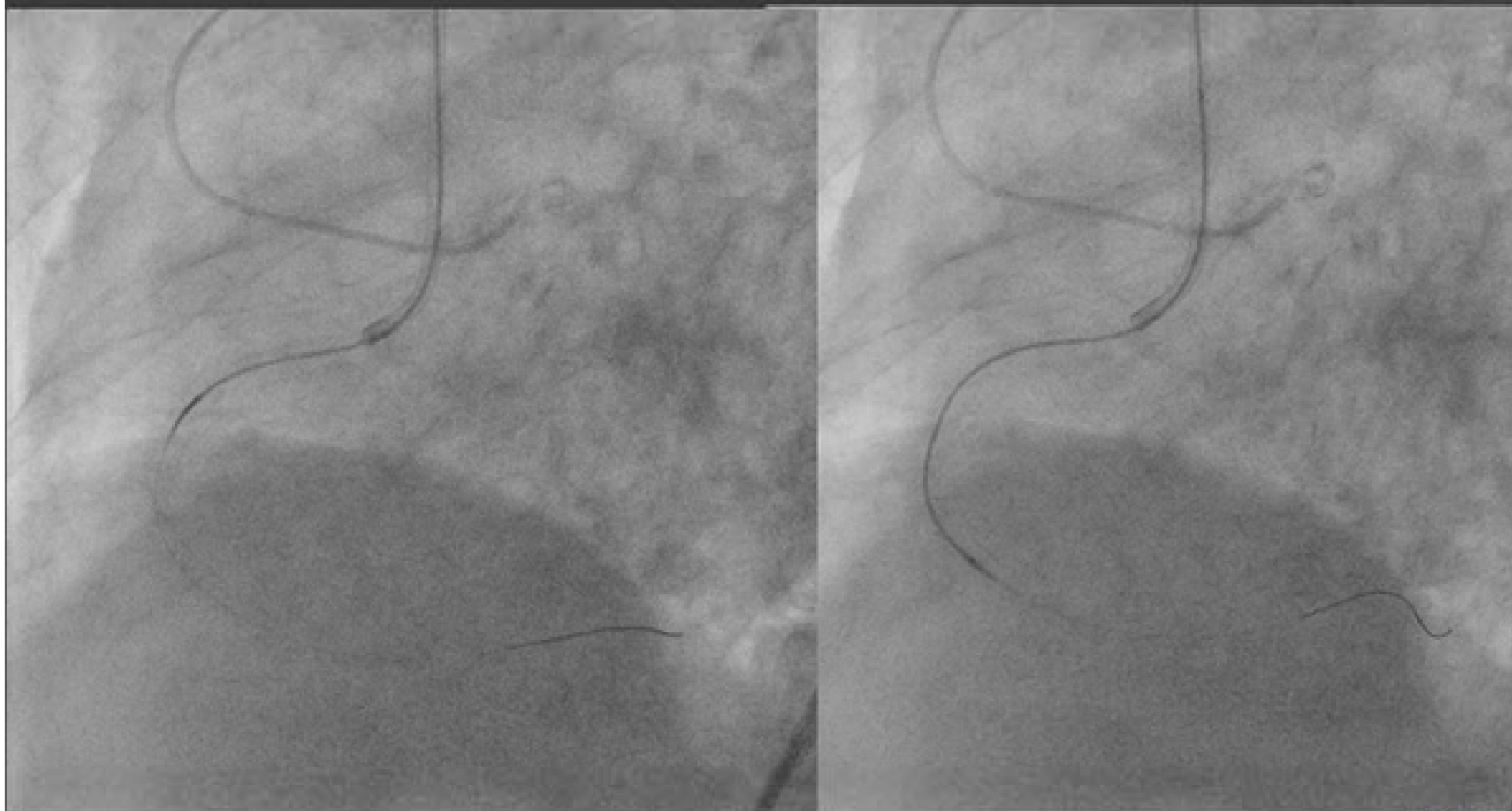
As A Penetration Catheter

- Good cross-ability after successful wiring
- No need of 1.25/1.5 mm balloon due to "Dotter" effect



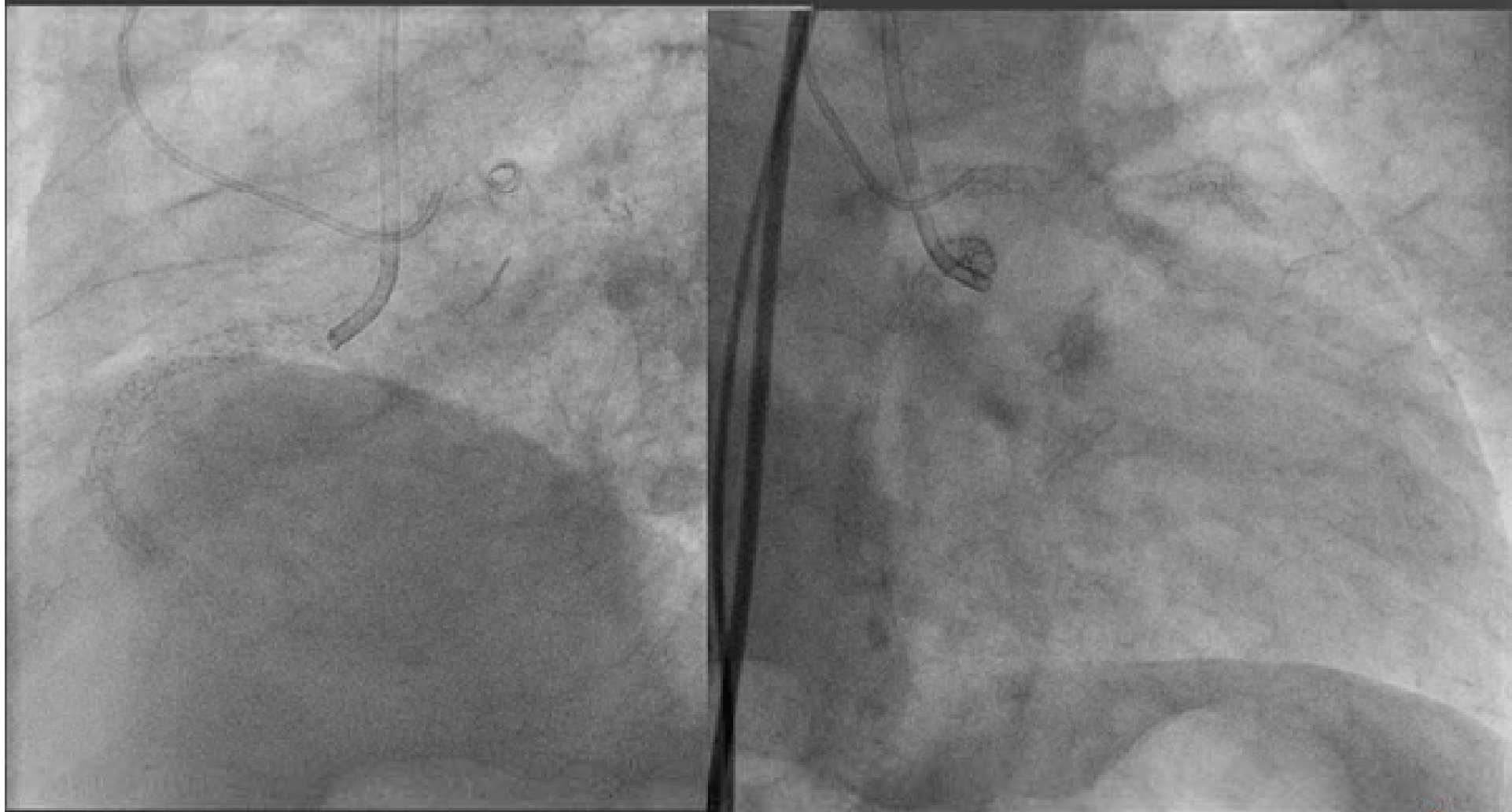

Corsair as Penetration Catheter



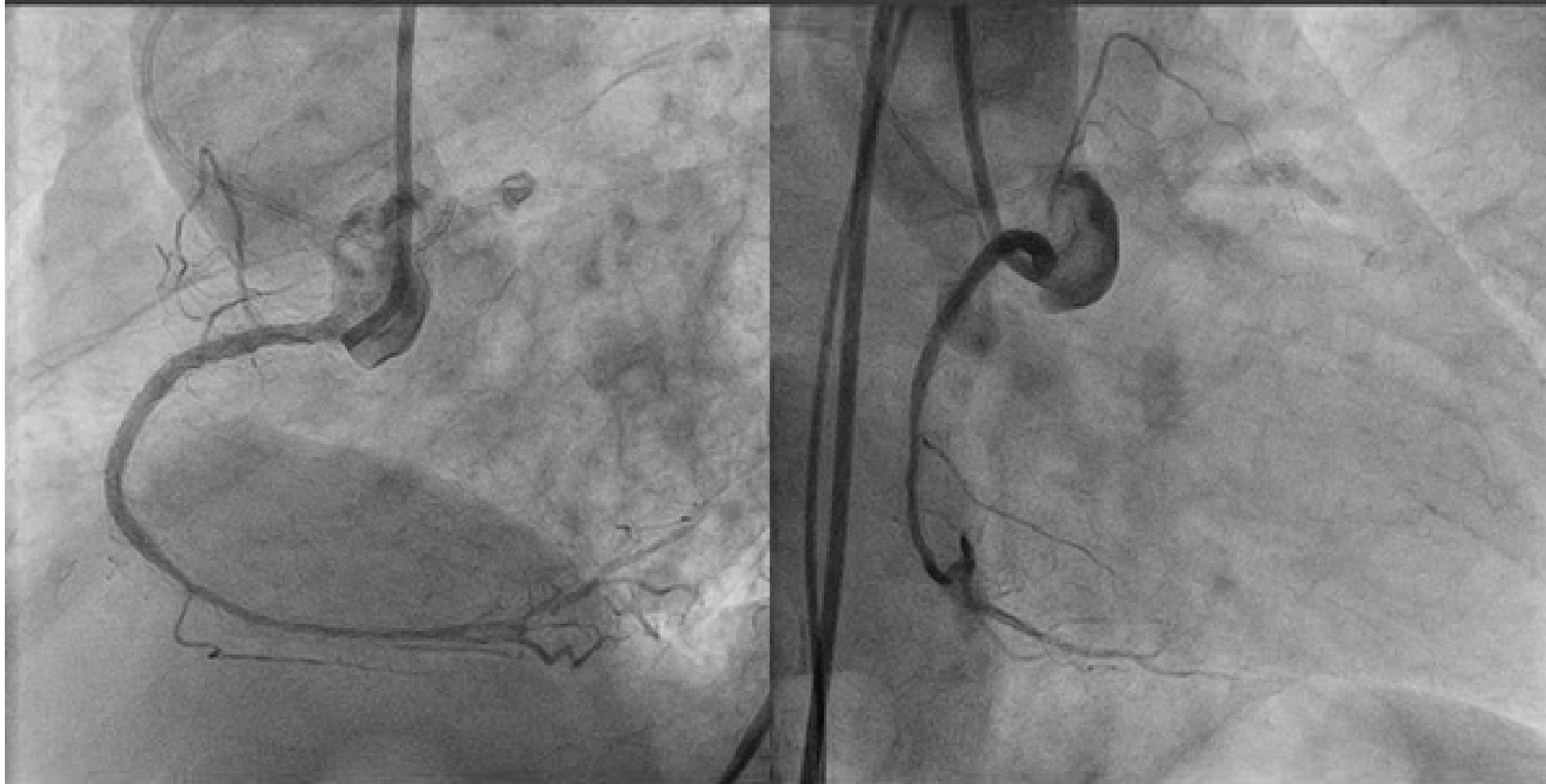


Final Angiogram



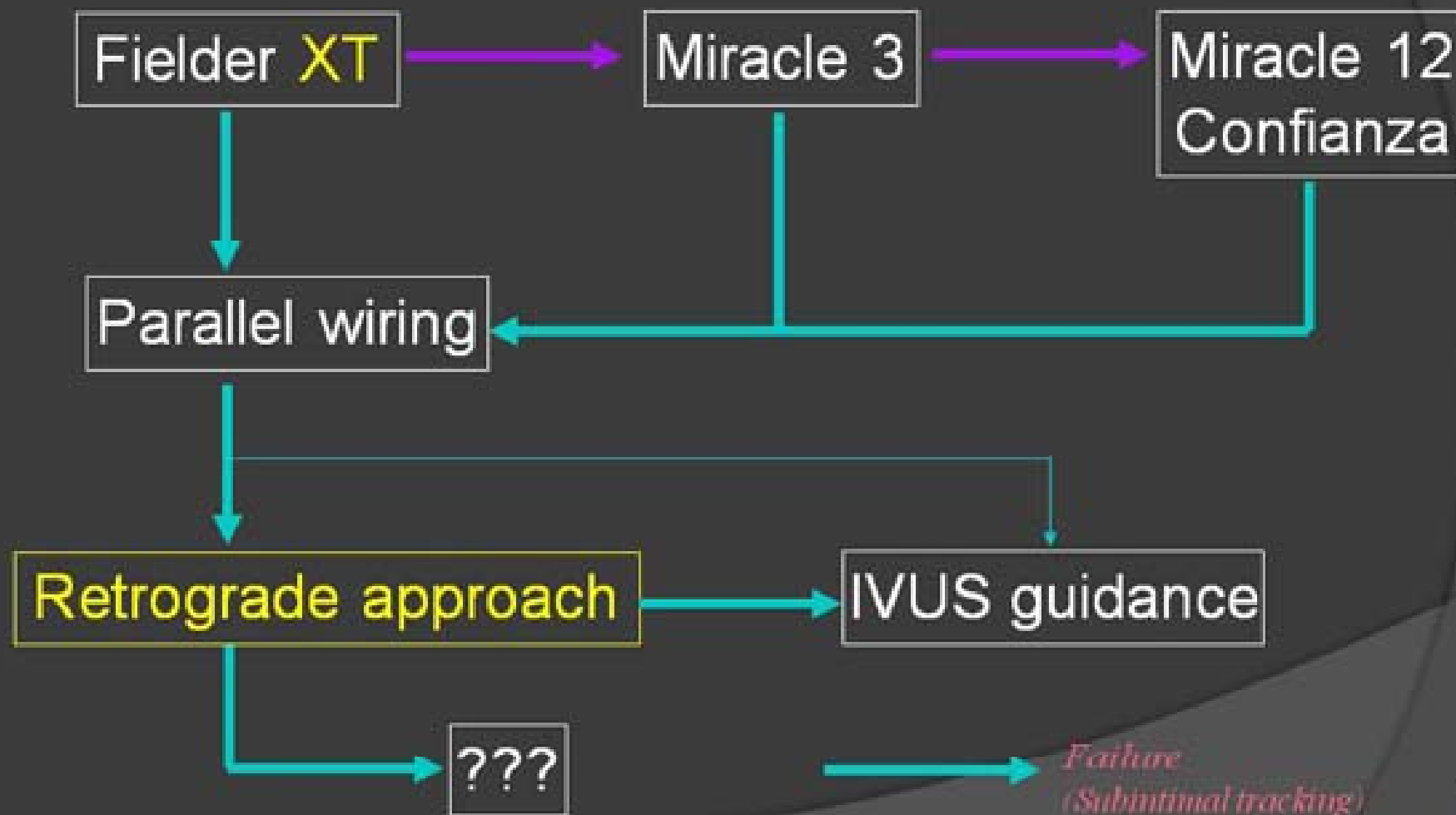


Final Angiogram





What is next?





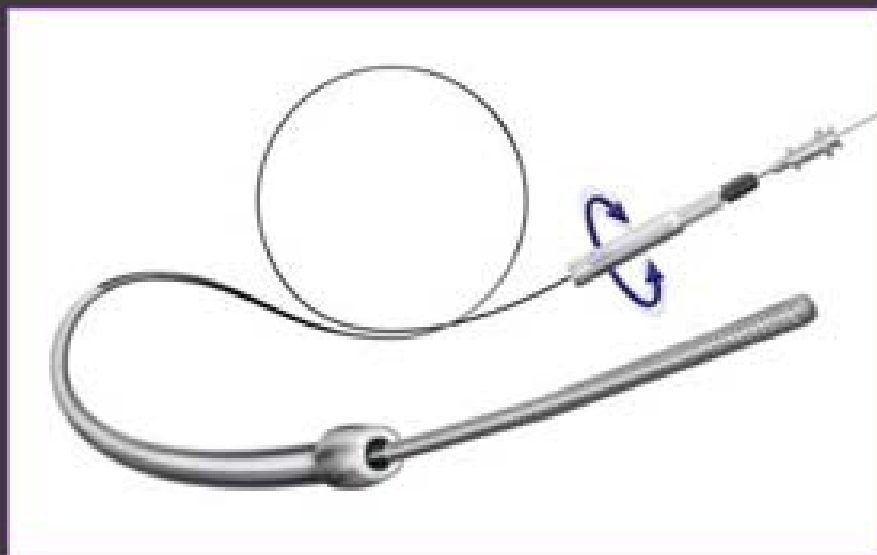
BRIDGEPOINT
MEDICAL

confidential

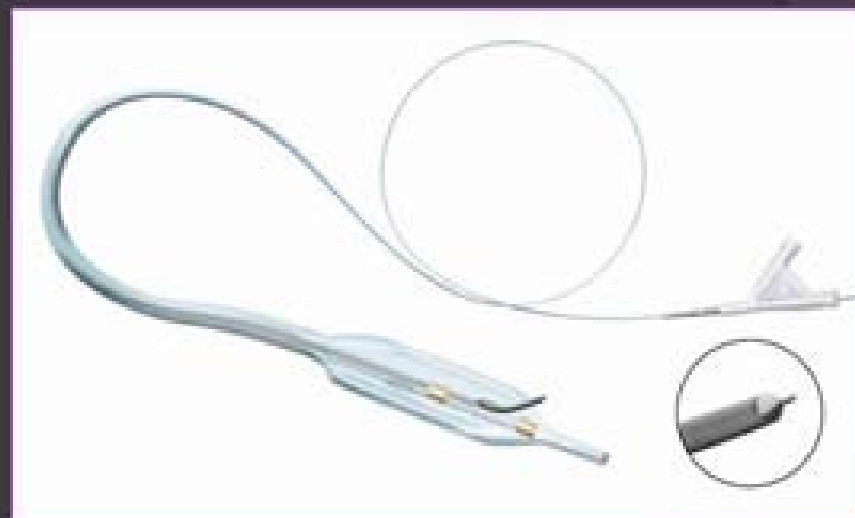


The BridgePoint System

CrossBoss CTO Catheter



Stingray CTO Re-Entry System

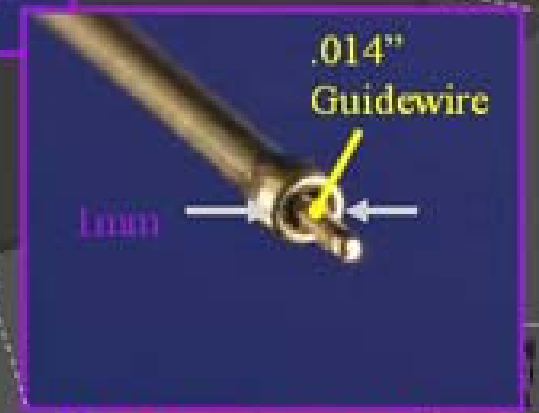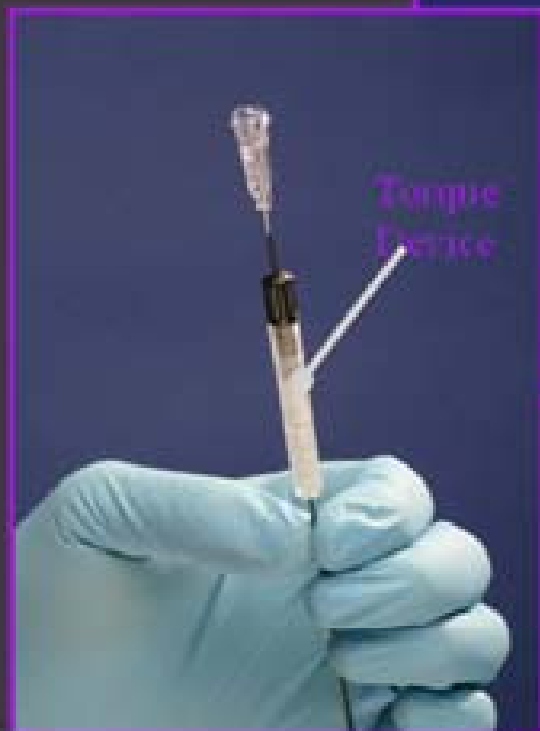

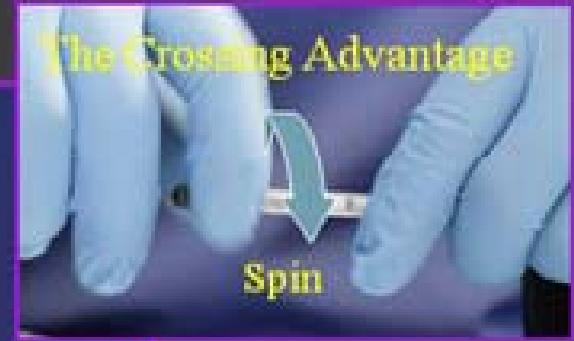


CrossBoss

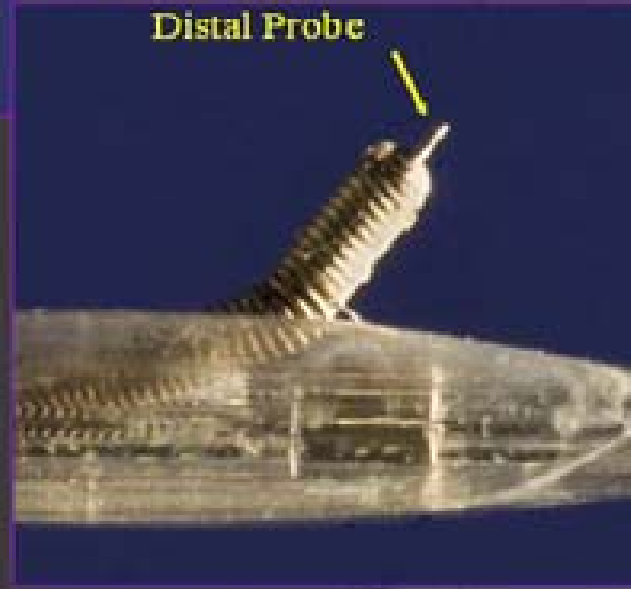




- .014" Compatible (OTW)
- Polyurethane-Hydrophilic Coated Coiled Wire Shaft
- 1 mm Atraumatic Distal Tip
- Torque Device
- Spin to Advance



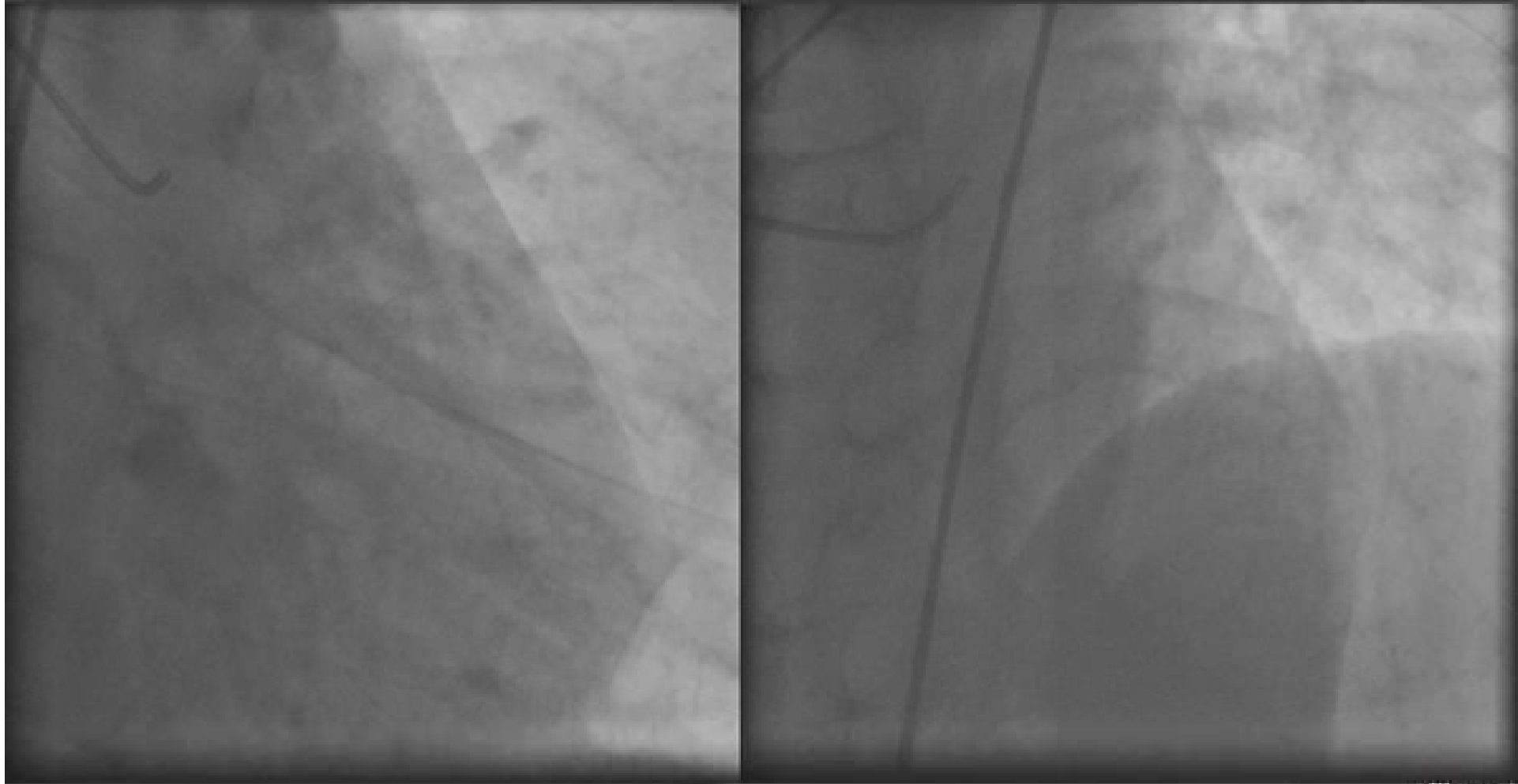


Stingray Balloon & Reentry Wire



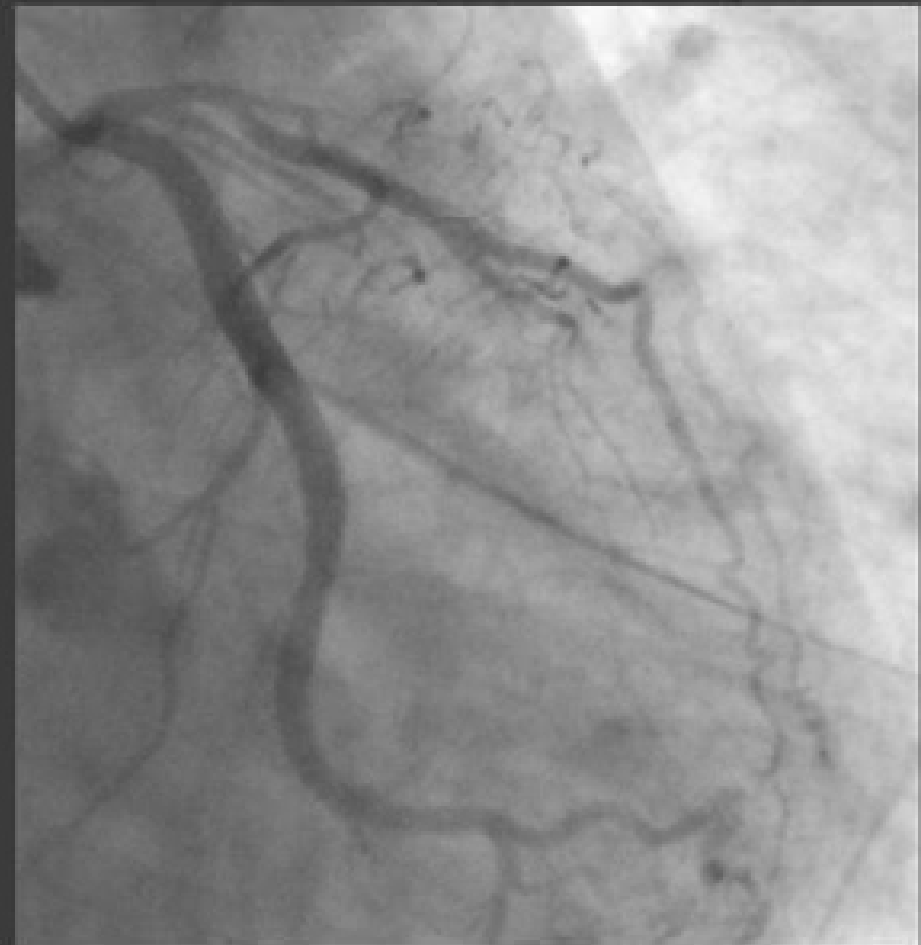
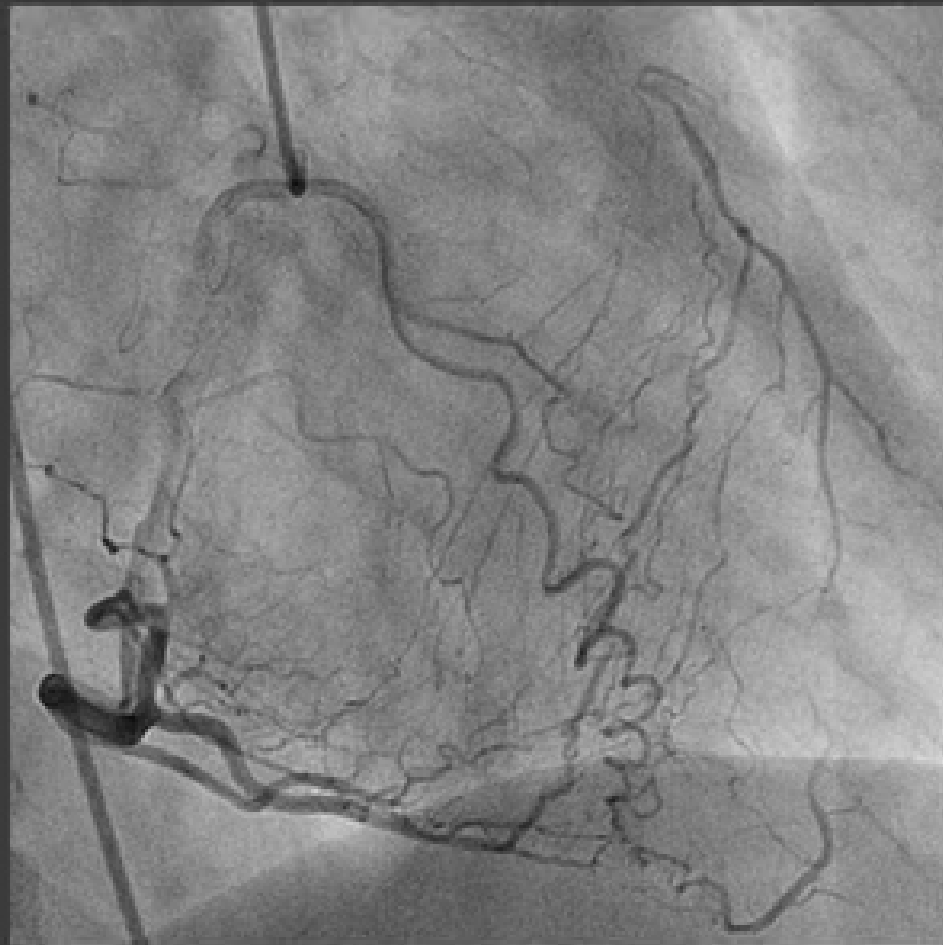
LAD CTO



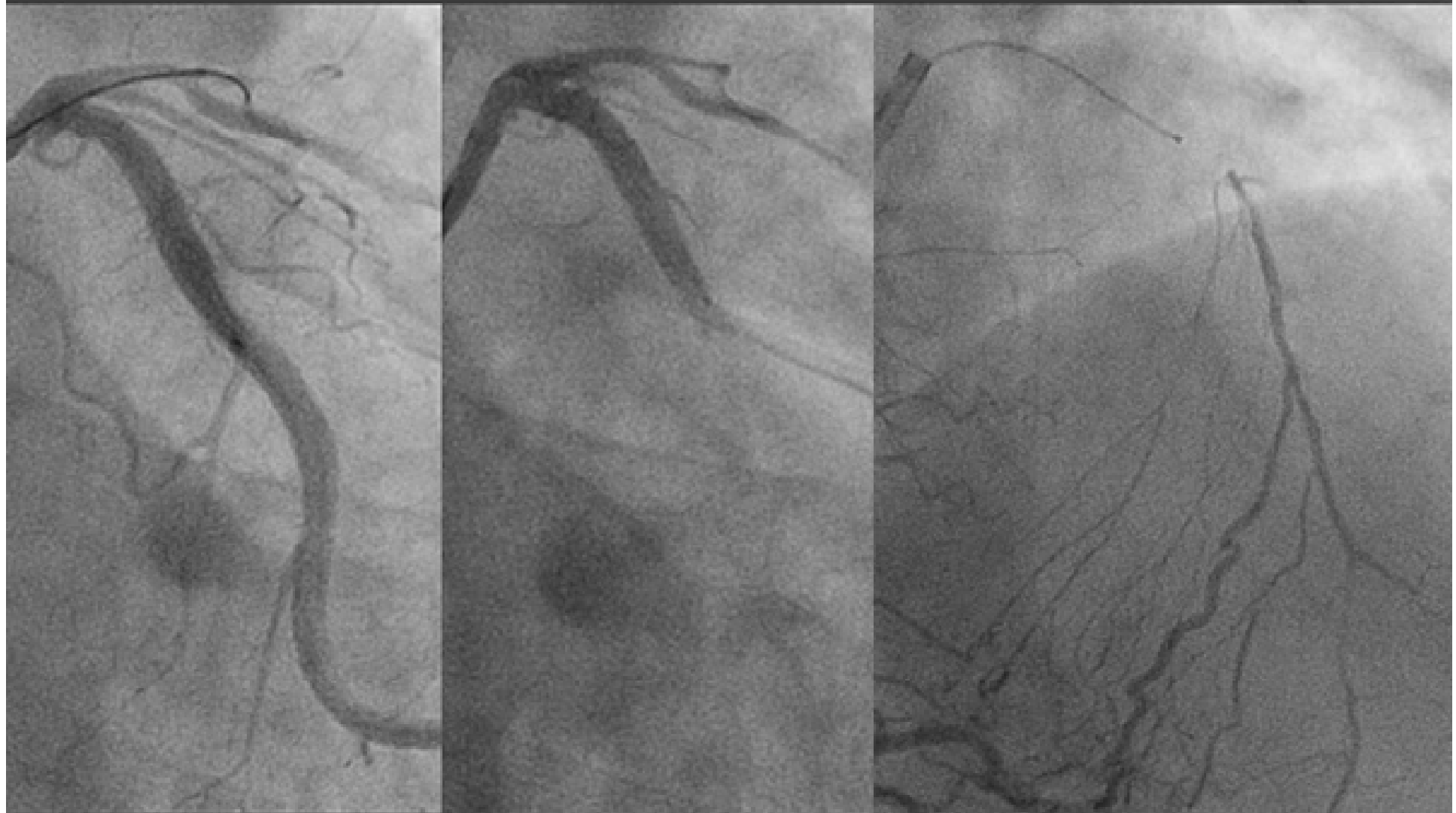

LAD CTO



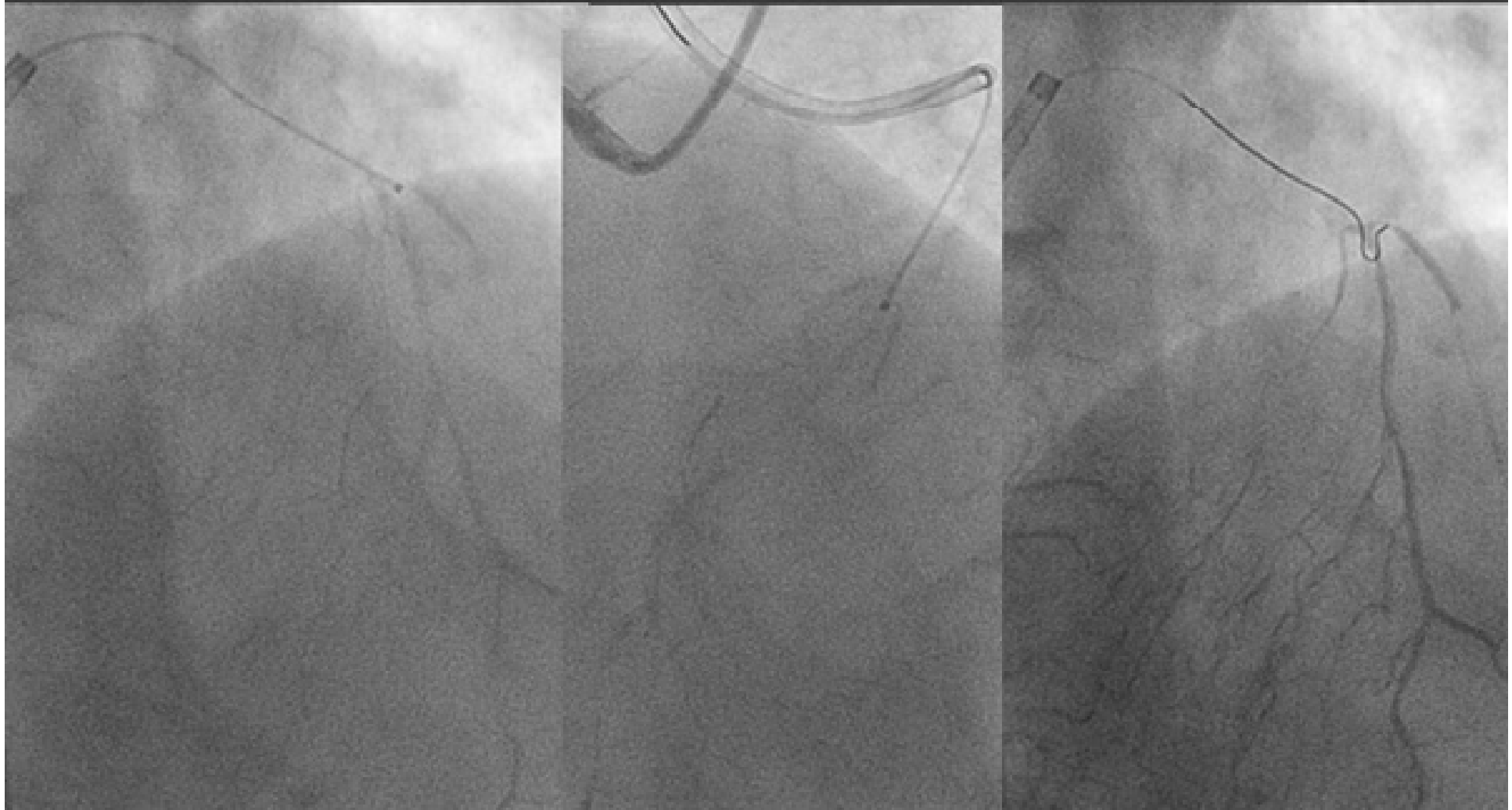

CrossBoss Catheter



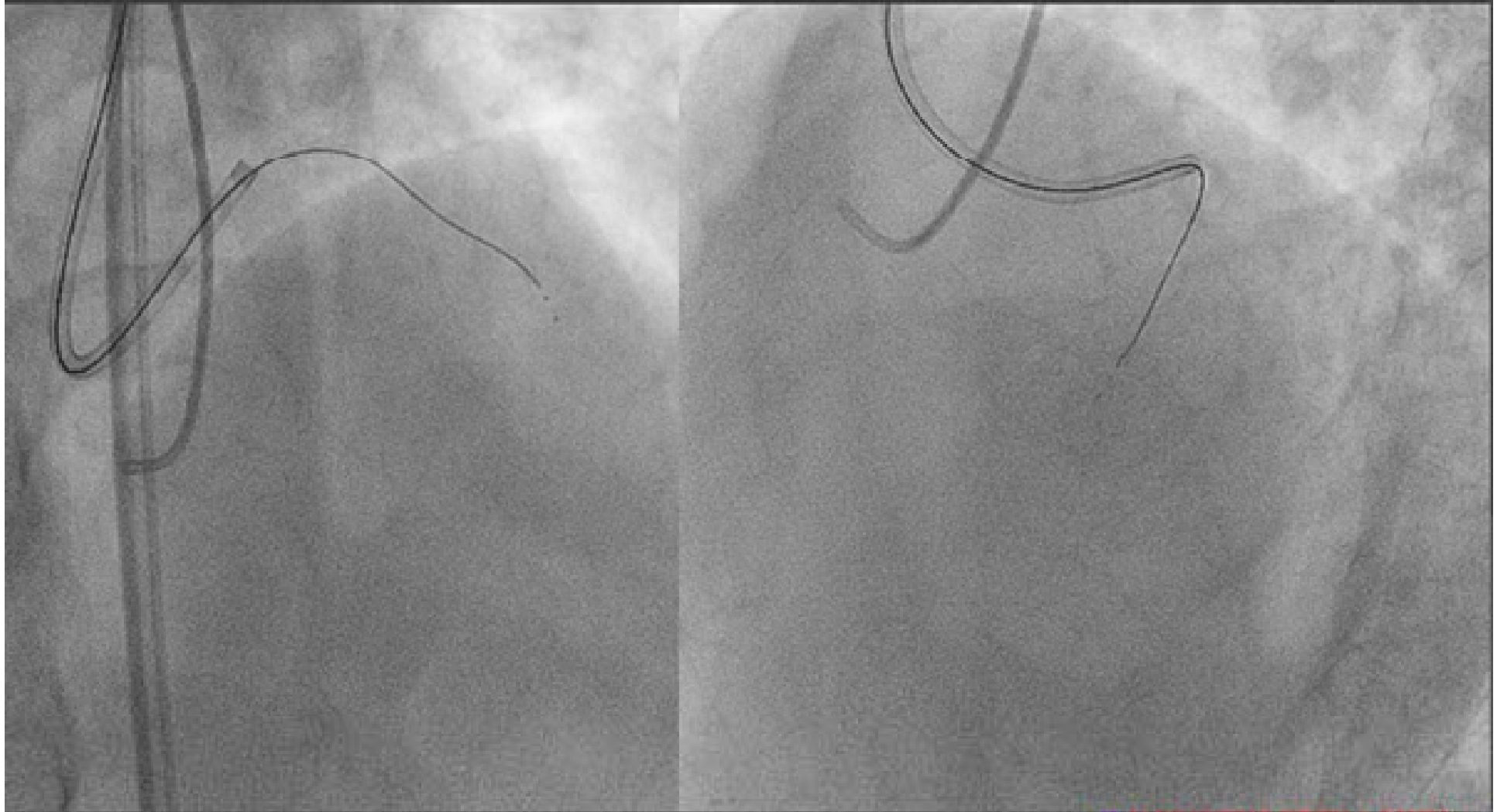


CrossBoss Catheter in Sub



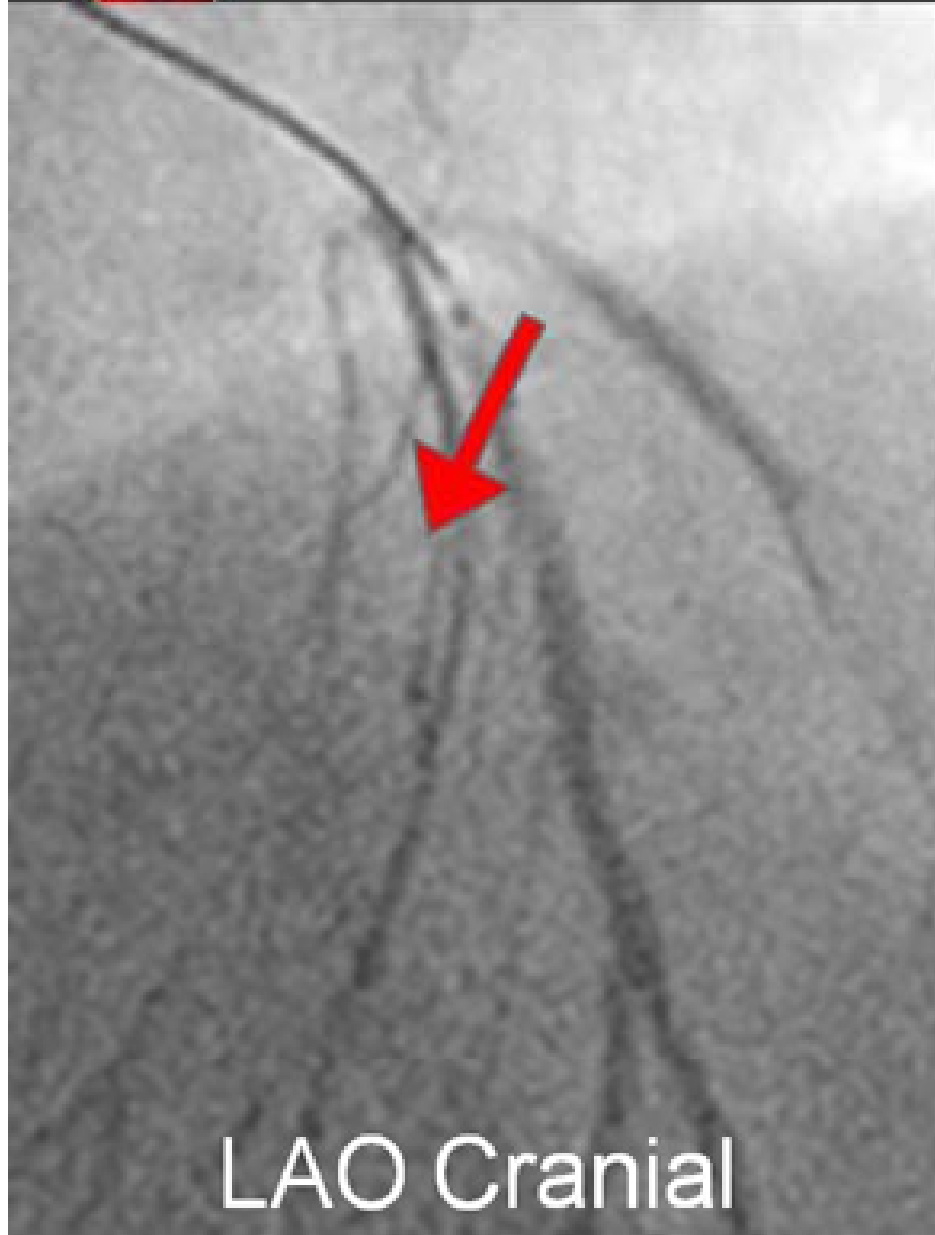


Stingray Balloon inflation

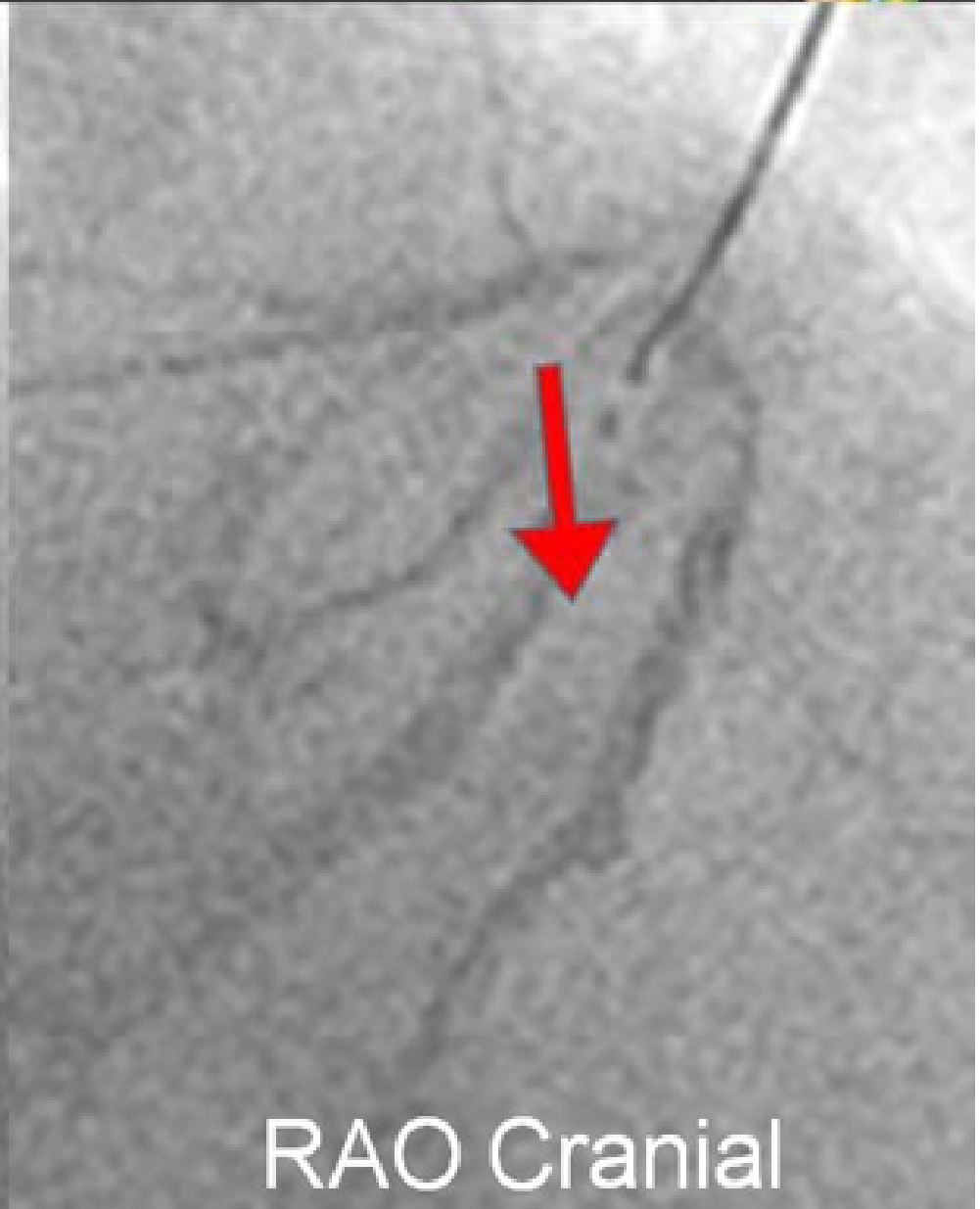




Penetration with re-entry wire



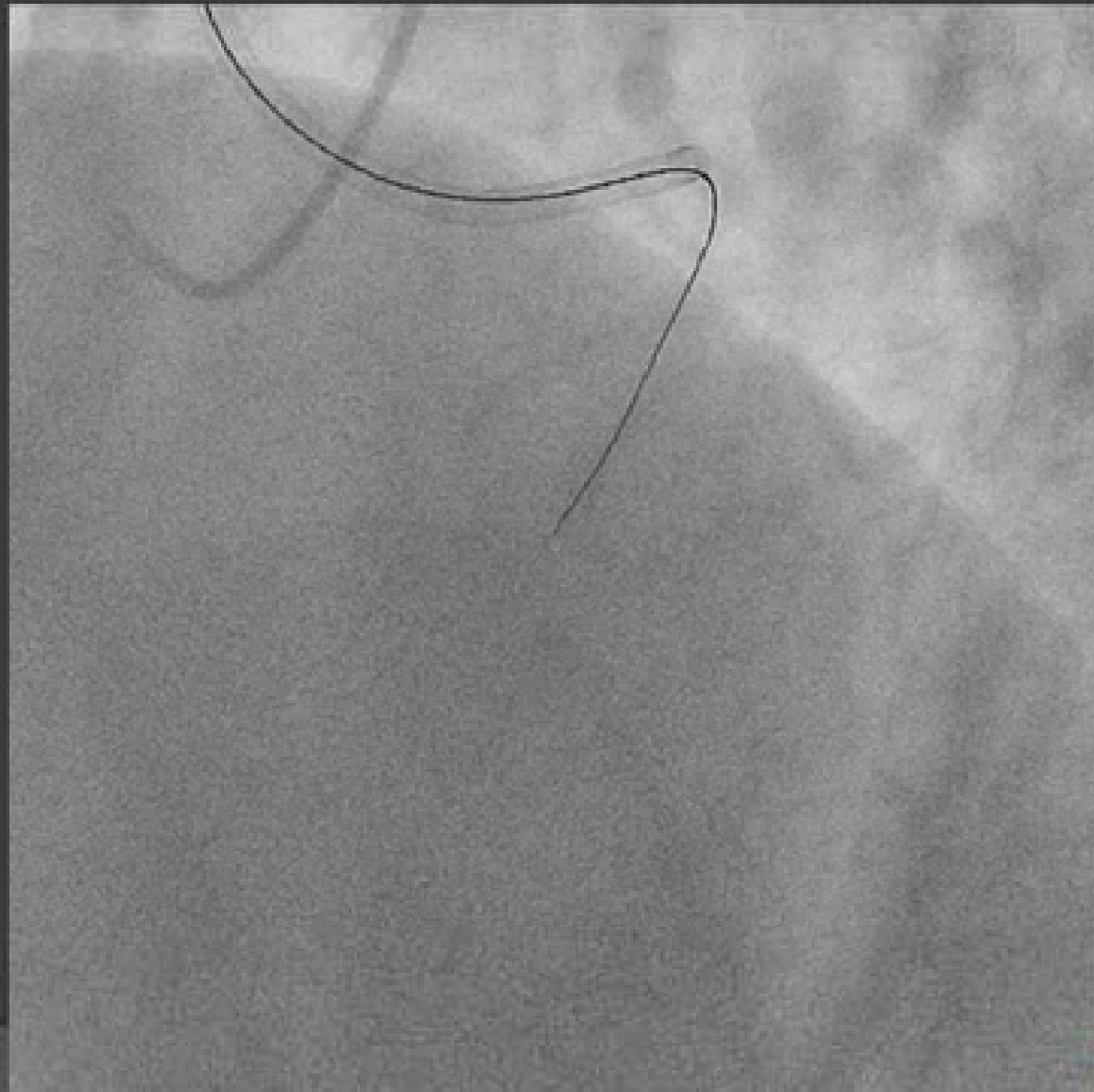
LAO Cranial



RAO Cranial

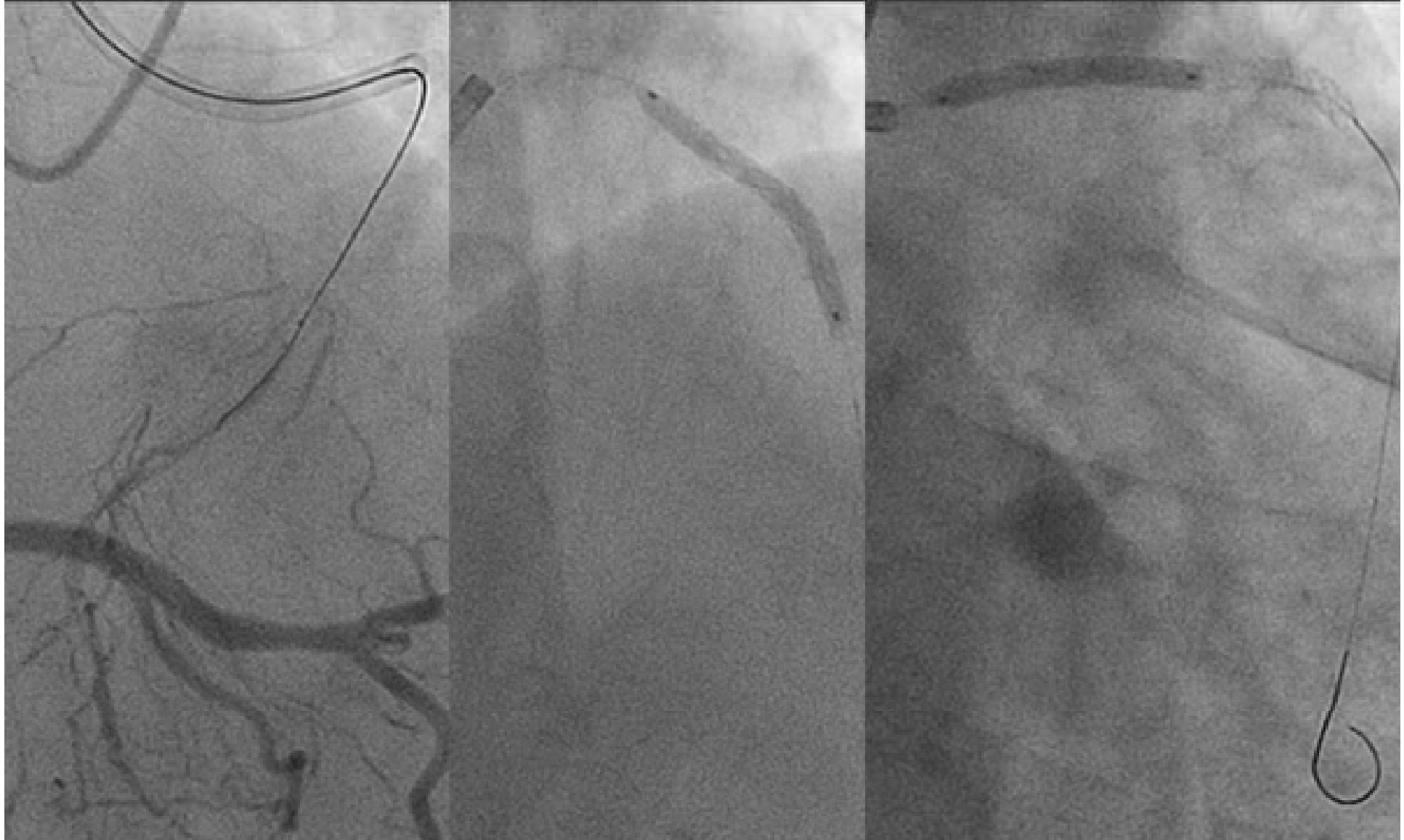


Penetration with re-entry wire



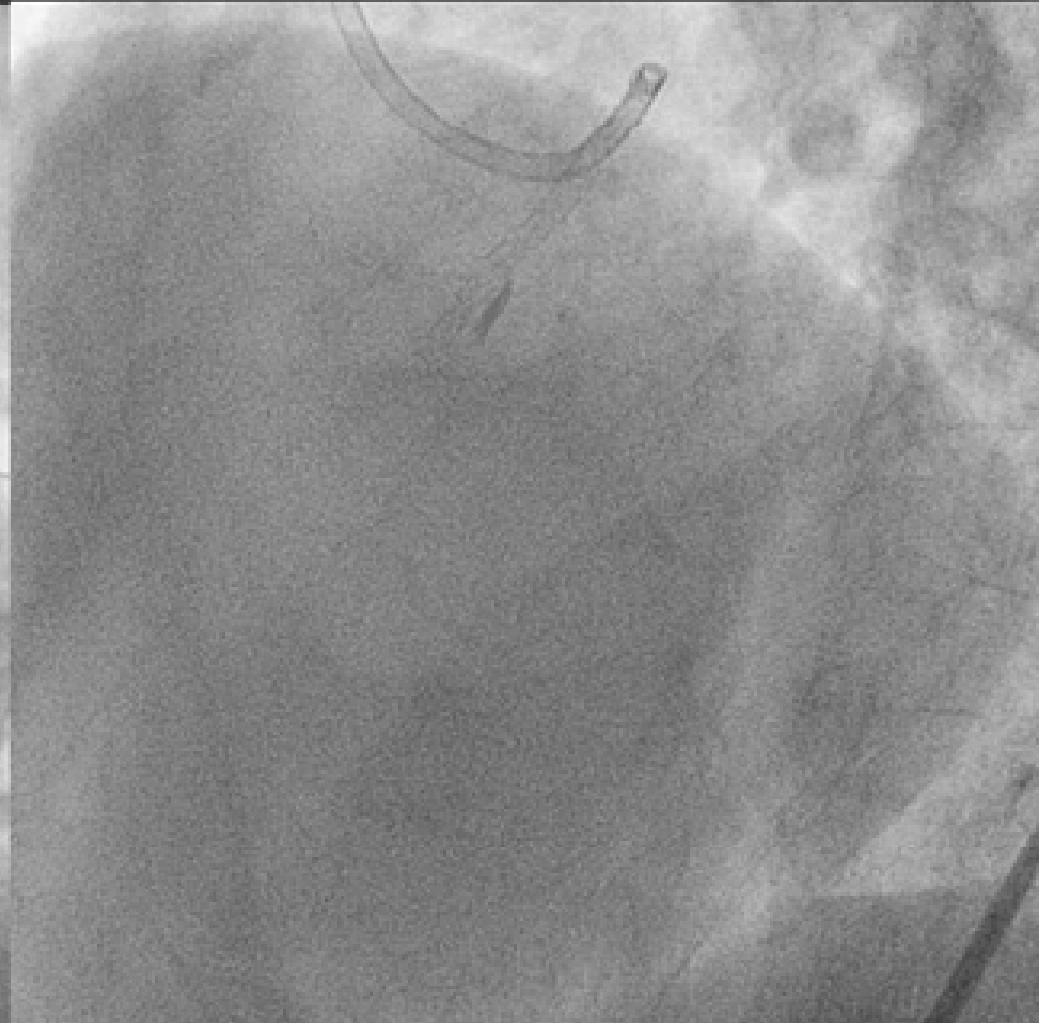
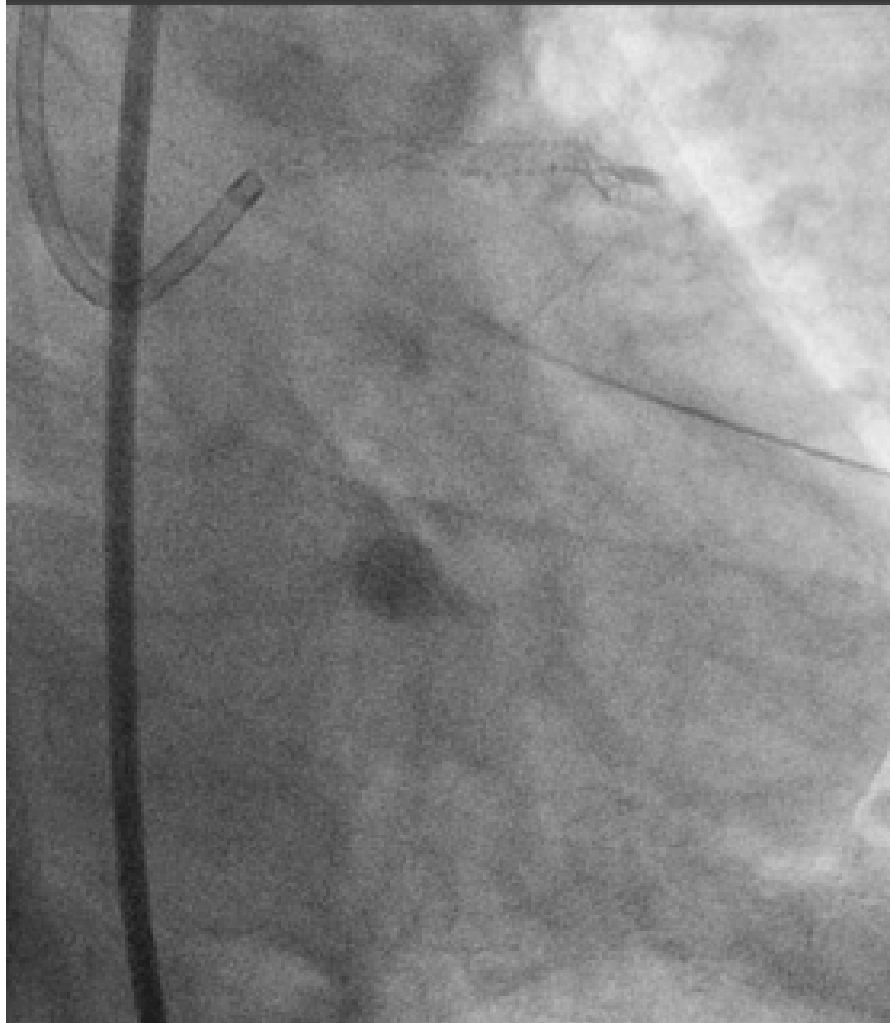


Stenting



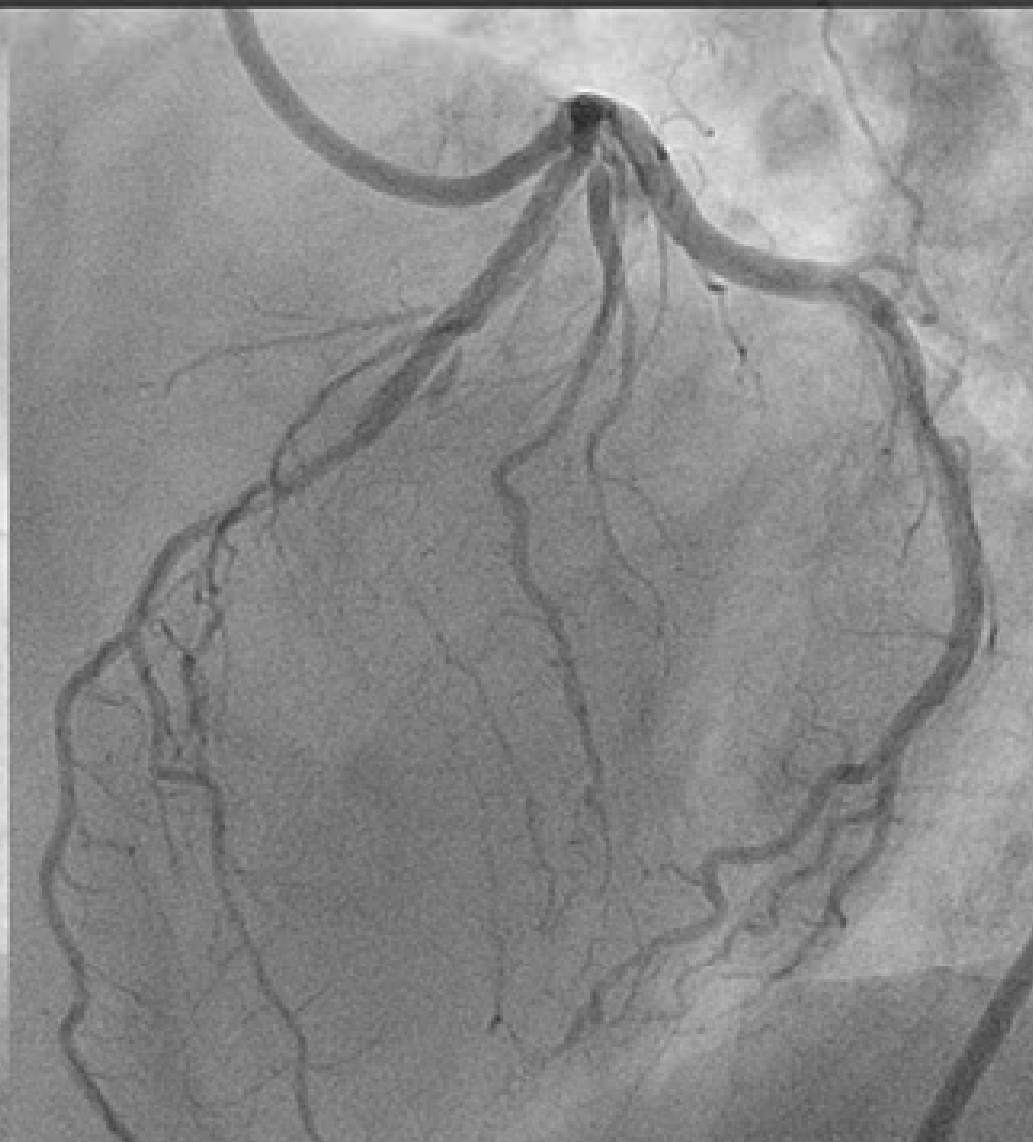
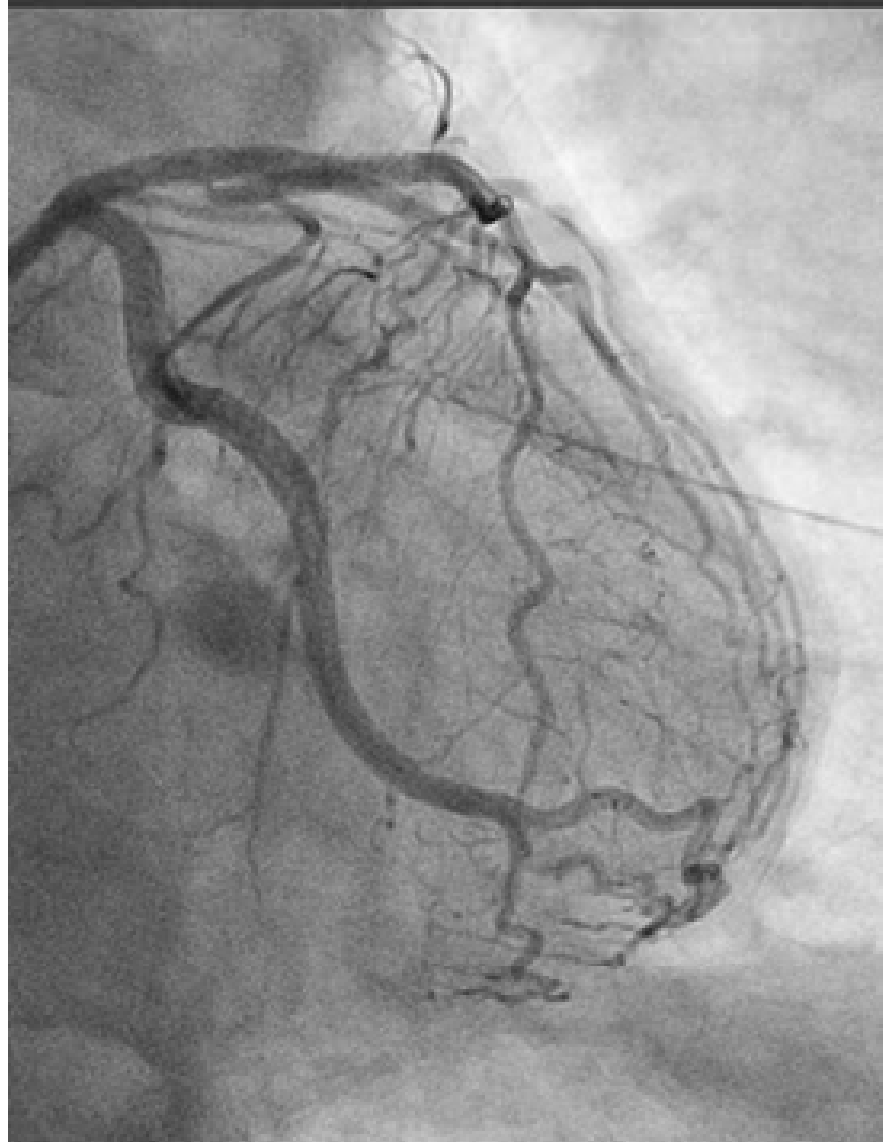
Final Angiogram



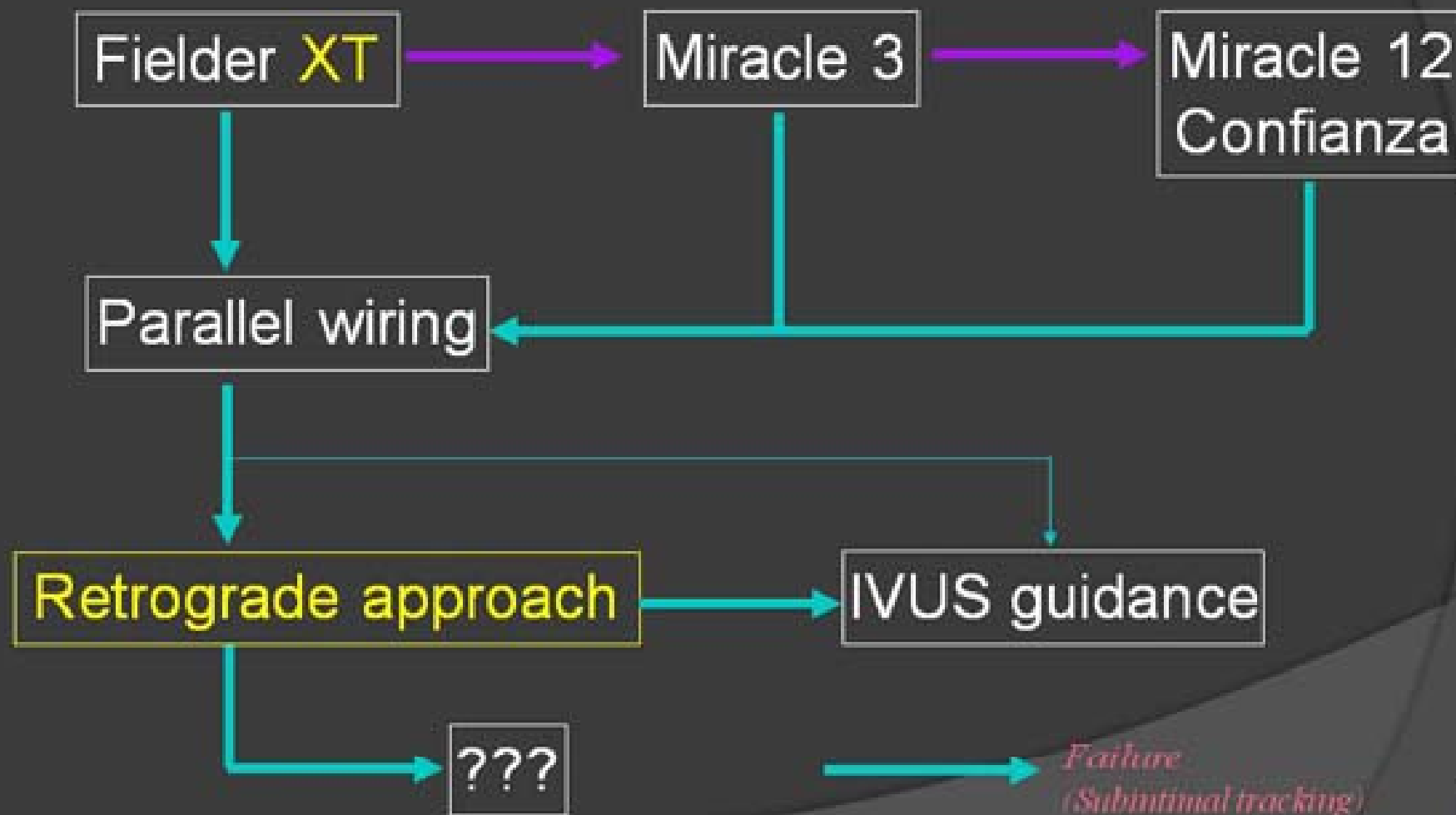


Final Angiogram





What is next?

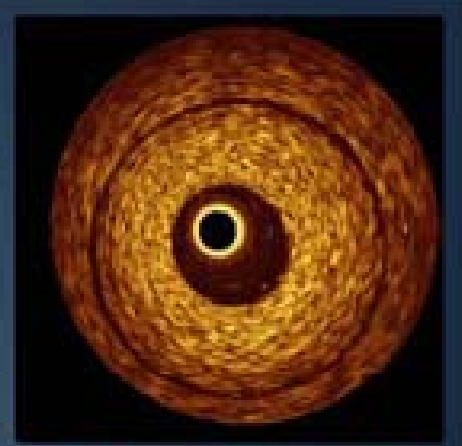
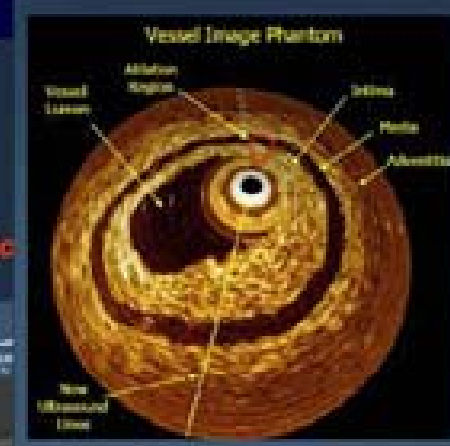
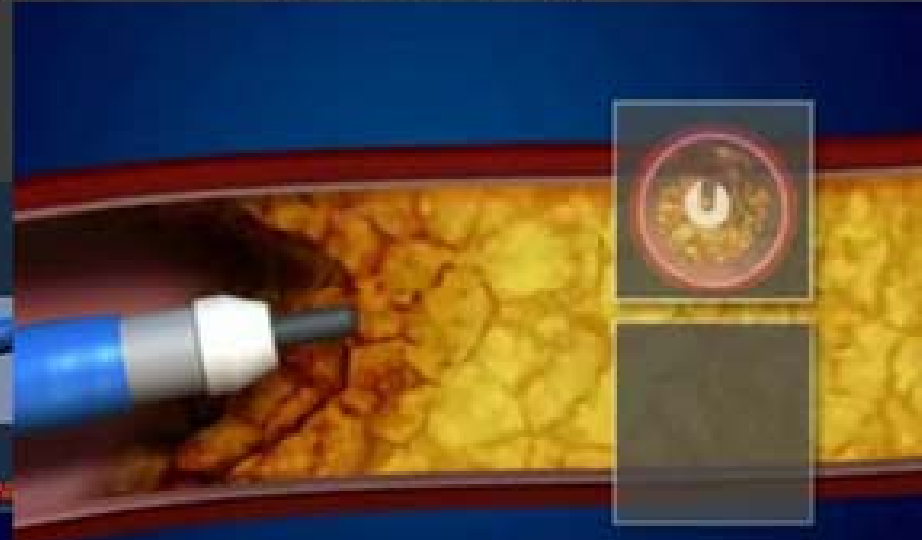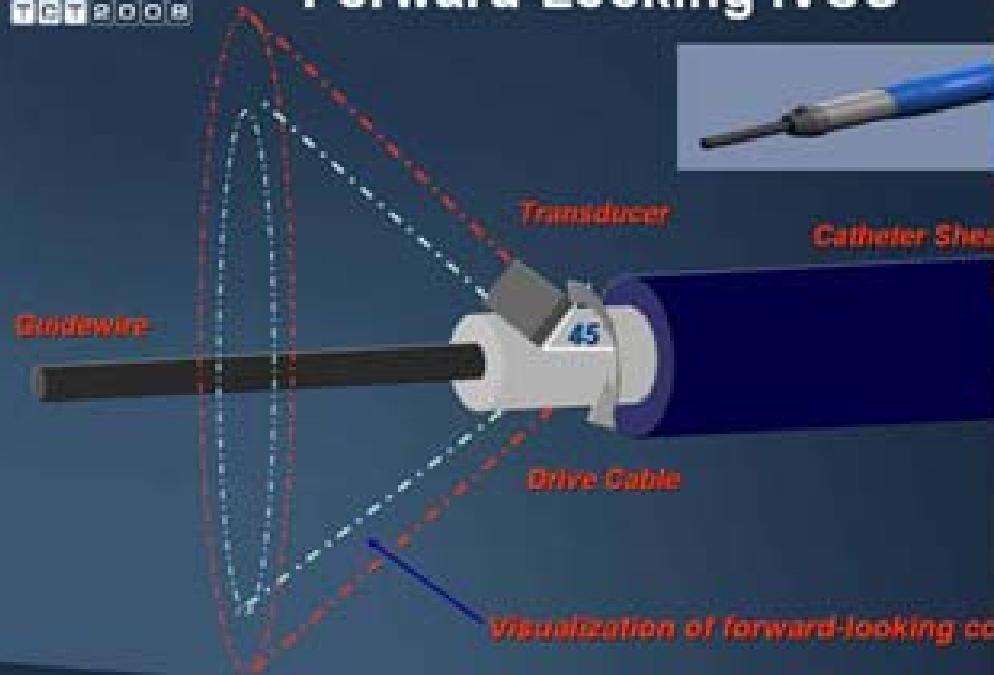




Forward Looking IVUS (Volcano, US)

20 YEARS OF INNOVATION
1998 2008

Forward-Looking IVUS



Flowing Artery with Guidewire Attached





Summary



- As the 1st attempt, Micro channel tracking with FielderXT is sometime feasible.
- Parallel wiring is still the “gold standard”.
- IVUS guided penetration is possible option as final method for me.
- Our success rate still mainly depends on the development of devices.
- Antegrade approach is , no doubt, still one of the most important method for CTOlesion.